Lo Studio dei Reperti Umani

(…ed accenni a quelli animali)

Diversi tipi di Resti…

Le mummie
“artificiali”…

Diversi tipi di Resti…

…Quelle “nature”…

Diversi tipi di Resti…

…Gli Scheletri…

Diversi tipi di Resti…

…E le “Vie di Mezzo”

I Protagonisti del Giorno

La Situazione sullo Scavo

LUOGHI DI SEPOLTURA:

- **Depositi geologici**
- **Terrapieni**
- **Antiche rovine**
- **Campi di battaglia**
- **Buche o fosse comuni**
- **Cave**
- **Cimiteri ordinari**

La Situazione sullo Scavo

TIPI DI SEPOLTURA:

- **Frammentaria**
- **Estesa (orientamento!!)**
- **Flessa**
- **Contorta**
- ***Cremazione***

La Situazione sullo Scavo

PRIMA DELL' ESTRAZIONE:

- **Assegnare n° di catalogazione**
- **Mettere a vista le ossa**
- **Pulire la fossa circostante**
- **Individuare orientamento**
- **Accertare la connessione (e mantenerla, al limite con bende imbevute di collanti temporanei idrosolubili**
- **Eseguire i rilievi (foto/disegni)**
- **Lasciar asciugare al sole le ossa**

La Situazione sullo Scavo

L' ESTRAZIONE:

- **Usare strumenti adatti**
- **Non fare "leva"**
- **Iniziare da un'estremità (capo/piedi) e proseguire**
- **Liberare le ossa dalla terra circostante e poi sollevarle, avvolgere il cranio in bende per le connessioni**
- **Inserire tutti i frammenti di un arto nello stesso "contenitore" esplicitando il contenuto**

… delicatezza!!! ...

Ma il bello viene dopo…

DOPO L' ESTRAZIONE:

- **Cautela nel trasporto**
- **Essiccamento (al sole se possibile, ed in scatole di cartone non stampato, causa assorbimento Pb confondente per studi paleonutrizionali)**
- **"Spazzolamento"**
- **Lavaggio con acqua (non sempre)**
- **Eventuale uso di consolidanti (resine)**

Ma il bello viene dopo…

RICOSTRUZIONE:

- **“Ripassino” di Anatomia**
- **Messa in connessione**
- **“Lettura interpretativa”**
- **Eventuale “reincollaggio”**

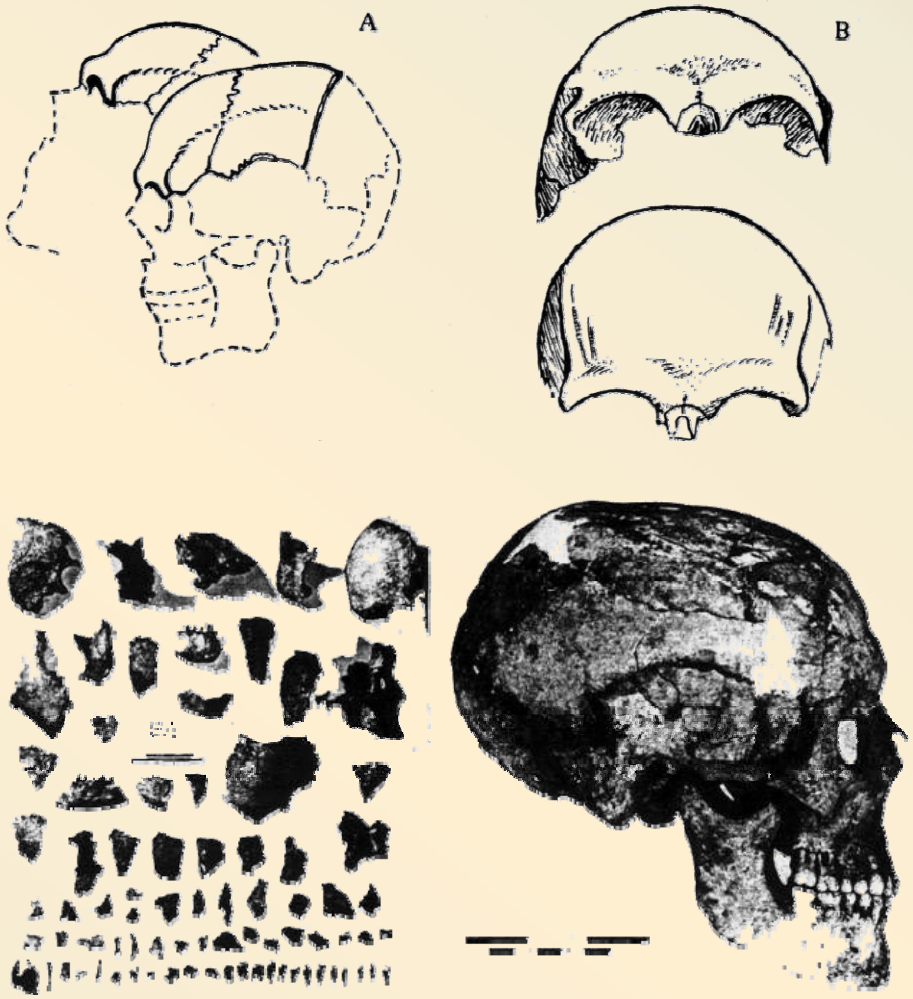

Ma il bello viene dopo…

STUDIO!!!

Table 8

An example of a recording sheet for basic use with skeletons

PERIOD	ARCHAEOLOGICAL REFS	FIELD OR MUSEUM NUMBER
LOCALITY	PRESERVATION	DEFORMATION (a.m. or p.m.)
SEX	AGE AT DEATH	STATURE (+ ref.)

DENTITION

8 7 6 5 4 3 2 1 | 1 2 3 4 5 6 7 8

8 7 6 5 4 3 2 1 | 1 2 3 4 5 6 7 8

X = loss a.m. C = caries U = unerupted
/ = loss p.m. A = abscess Ó = erupting
E = pulp exposure

ATTRITION

M_1		M_2		M_3	
U	L	U	L	U	L

CARIES	in	ABSCESSES	in	ENAMEL HYPOPLASIA	in
TOOTH LOSS a.m.	in	PERIODONTAL DISEASE		CALCULUS	in
WORMIAN BONES		INCA BONE		METOPISM	
PARIETAL NOTCH BONES		EPIPTERIC BONES		PTERION	
TORI MANDIBULARES		TORI AUDITIVI		TORUS PALATINUS	
TORI MAXILLARES		OSTEOPOROSIS (ORBITS)		INJURY	
DISEASE (*a*) Arthritis					
(*b*) Other changes					

BASIC MEASUREMENTS

		Orbital B	(O'_1)
SKULL		Orbital Ht.	(O_2)
Maximum L	(L)	Palatal L	(G'_2)
Maximum B	(B)	Palatal B	(G_2)
Basi-Breg. Ht.	(H')	FEMUR	
Frontal Arc	(S_1)	Maximum L	(FeL_1)
Parietal Arc	(S_2)	TIBIA	
Occipital Arc	(S_3)	Maximum L	(TiL_1)
Basi-Nasal L	(LB)	HUMERUS	
Basi-Alv. L	(GL)	Maximum L	(HuL_1)
Upper Facial Ht.	(G'H)	RADIUS	
Bimaxillary B	(GB)	Maximum L	(RaL_1)
Nasal Ht.	(NH')	ULNA	
Nasal B	(NB)	Maximum L	(UlL_1)

N.B. The following symbols are an aid to quick notation:
/ = present (coded 1)
X = absent (coded 0)
— = not possible to ascertain owing to condition of bone
a.m.; p.m. = ante-mortem; post-mortem.

Strumenti di “Supporto”

ANALISI di LABORATORIO:

- **Gruppi sanguigni**
- ***Radiocarbonio 14***
- **TAC, RMN, RX…**
- **DNA (!!!)**
- **Immunofluorescenza**
- **Composti azotati (a.a., capelli…)**

Strumenti di “Supporto”

STRUMENTAZIONE:

- **“Compassi”**
- **Tavola osteometrica**
- **Metro**
- **Lente di ingrandimento**

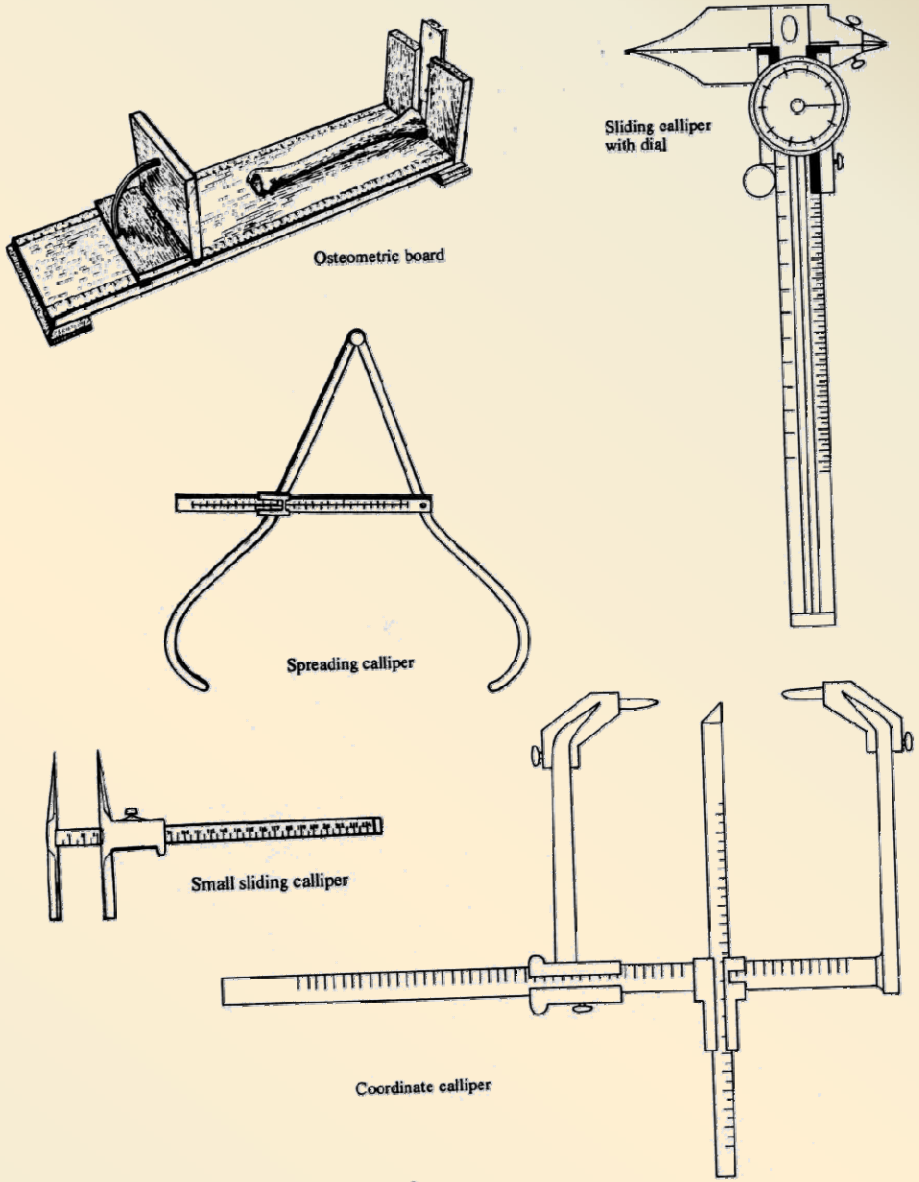

Figure 4.1 Instruments for measuring bones.

Cosa cerchiamo?

Table 8

An example of a recording sheet for basic use with skeletons

PERIOD	ARCHAEOLOGICAL REFS	FIELD OR MUSEUM NUMBER
LOCALITY	PRESERVATION	DEFORMATION (a.m. or p.m.)
SEX	AGE AT DEATH	STATURE (+ ref.)

DENTITION

8 7 6 5 4 3 2 1 | 1 2 3 4 5 6 7 8

8 7 6 5 4 3 2 1 | 1 2 3 4 5 6 7 8

X = loss a.m. C = caries Ʊ = unerupted
/ = loss p.m. A = abscess Ó = erupting
E = pulp exposure

ATTRITION

M_1		M_2		M_3	
U	L	U	L	U	L

CARIES	in	ABSCESSES	in	ENAMEL HYPOPLASIA	in
TOOTH LOSS a.m.	in	PERIODONTAL DISEASE		CALCULUS	in
WORMIAN BONES		INCA BONE		METOPISM	
PARIETAL NOTCH BONES		EPIPTERIC BONES		PTERION	
TORI MANDIBULARES		TORI AUDITIVI		TORUS PALATINUS	
TORI MAXILLARES		OSTEOPOROSIS (ORBITS)		INJURY	
DISEASE (*a*) Arthritis					
(*b*) Other changes					

BASIC MEASUREMENTS

SKULL		Orbital B	(O'_1)
Maximum L	(L)	Orbital Ht.	(O_2)
Maximum B	(B)	Palatal L	(G'_2)
Basi-Breg. Ht.	(H')	Palatal B	(G_2)
Frontal Arc	(S_1)	FEMUR	
Parietal Arc	(S_2)	Maximum L	(FeL_1)
Occipital Arc	(S_3)	TIBIA	
Basi-Nasal L	(LB)	Maximum L	(TiL_1)
Basi-Alv. L	(GL)	HUMERUS	
Upper Facial Ht.	(G'H)	Maximum L	(HuL_1)
Bimaxillary B	(GB)	RADIUS	
Nasal Ht.	(NH')	Maximum L	(RaL_1)
Nasal B	(NB)	ULNA	
		Maximum L	(UlL_1)

N.B. The following symbols are an aid to quick notation:
/ = present (coded 1)
X = absent (coded 0)
— = not possible to ascertain owing to condition of bone
a.m.; p.m. = ante-mortem; post-mortem.

"Carta d'Identità"

Malattie e Varianti Anatomiche

Misure Fondamentali

Ma prima un po' di Anatomia…

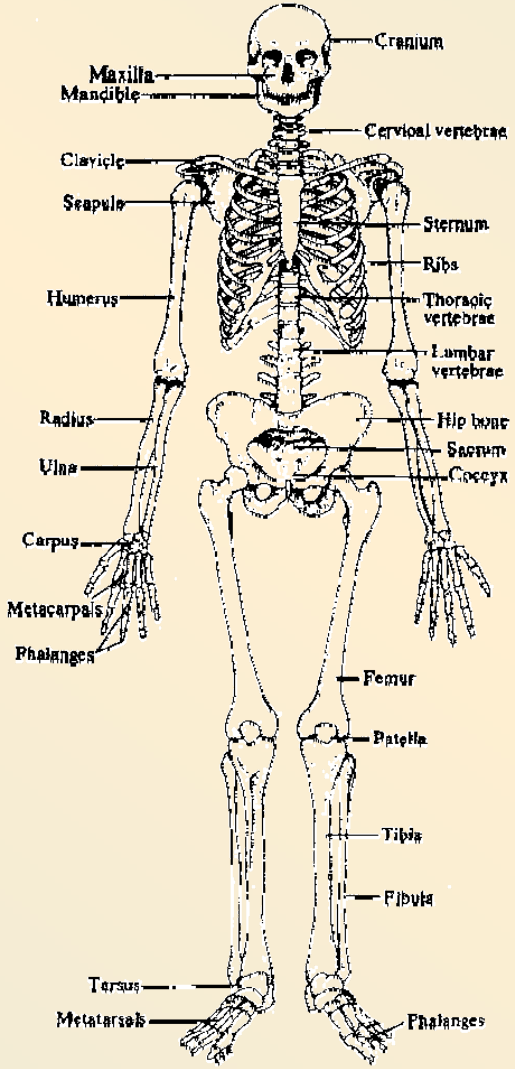

Figure 2.1 The human skeleton

Ma prima un po’ di Anatomia…

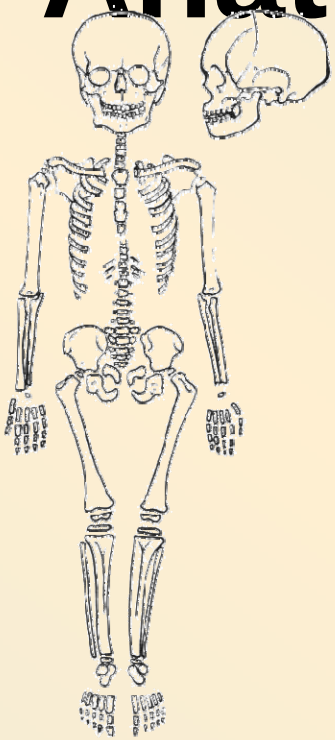

Figure 2.13 Standard checking sheet, 3 year old.

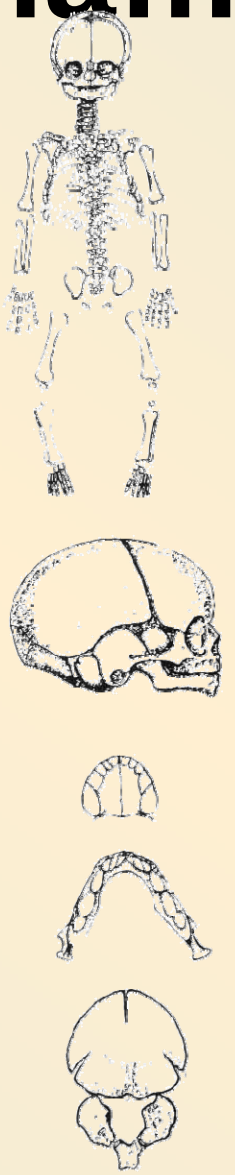

Figure 2.14 Standard checking sheet, embryo.

Ma prima un po' di Anatomia…

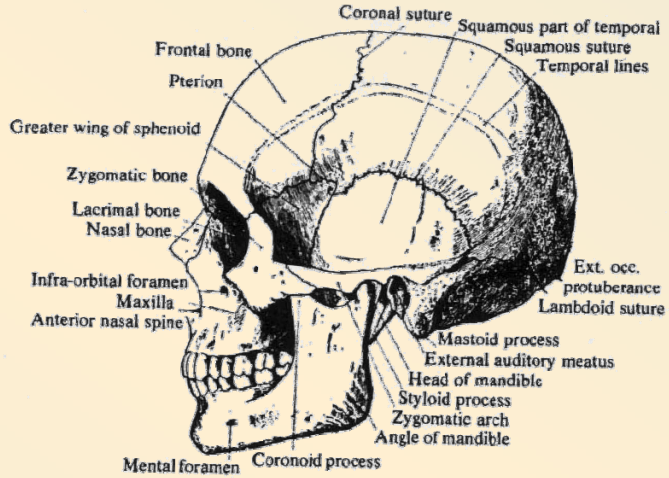

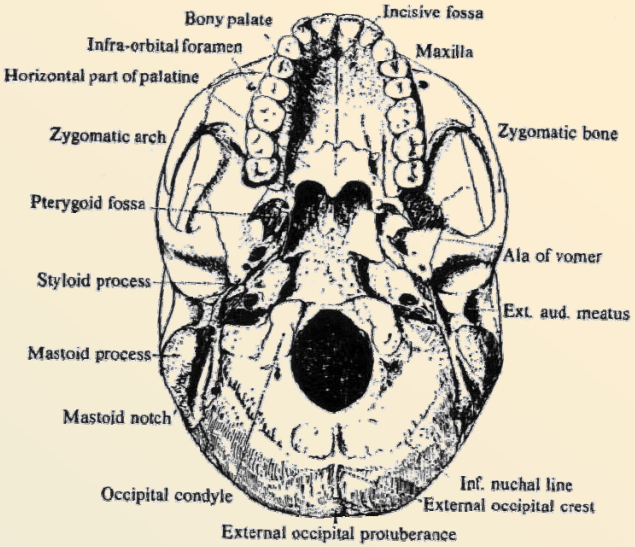

Ma prima un po' di Anatomia…

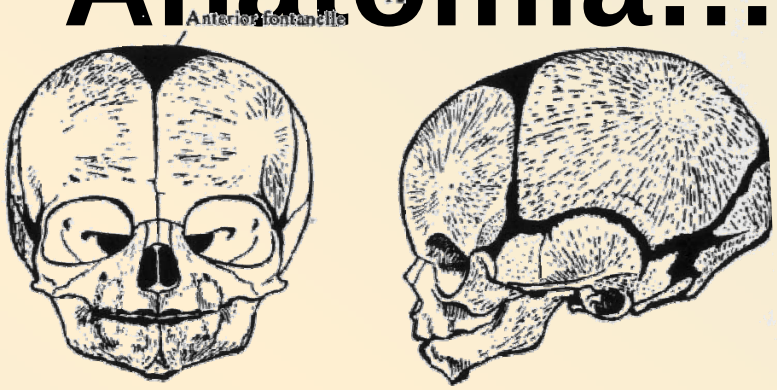

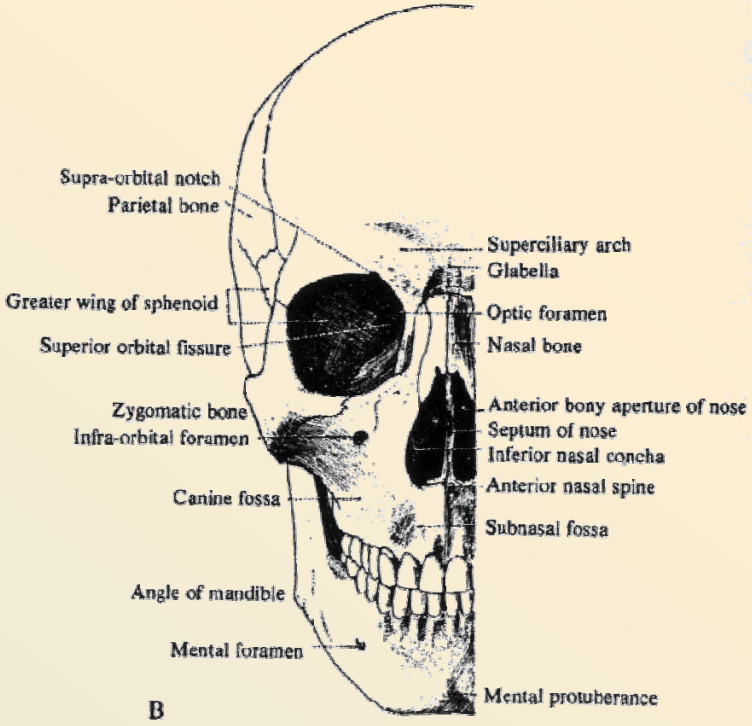

Ma prima un po’ di Anatomia…

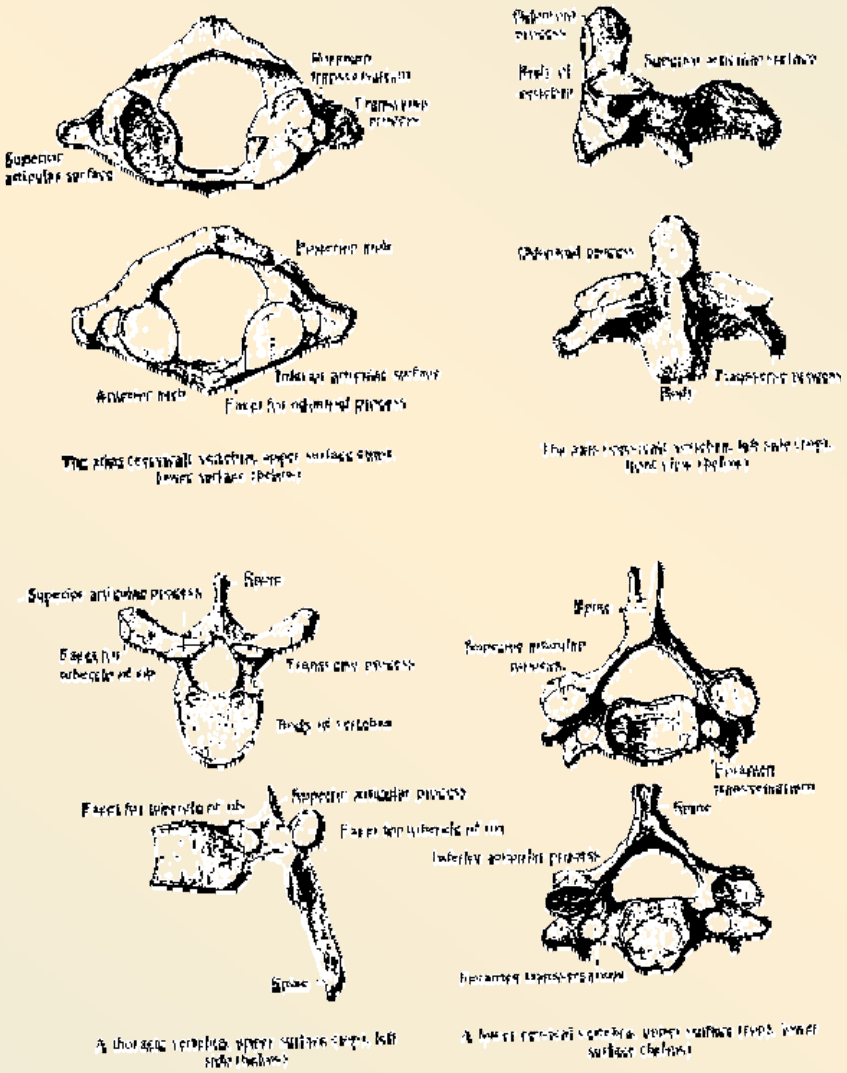

Figure 2-4 Characteristics of cervical and thoracic vertebrae.

Ma prima un po' di Anatomia…

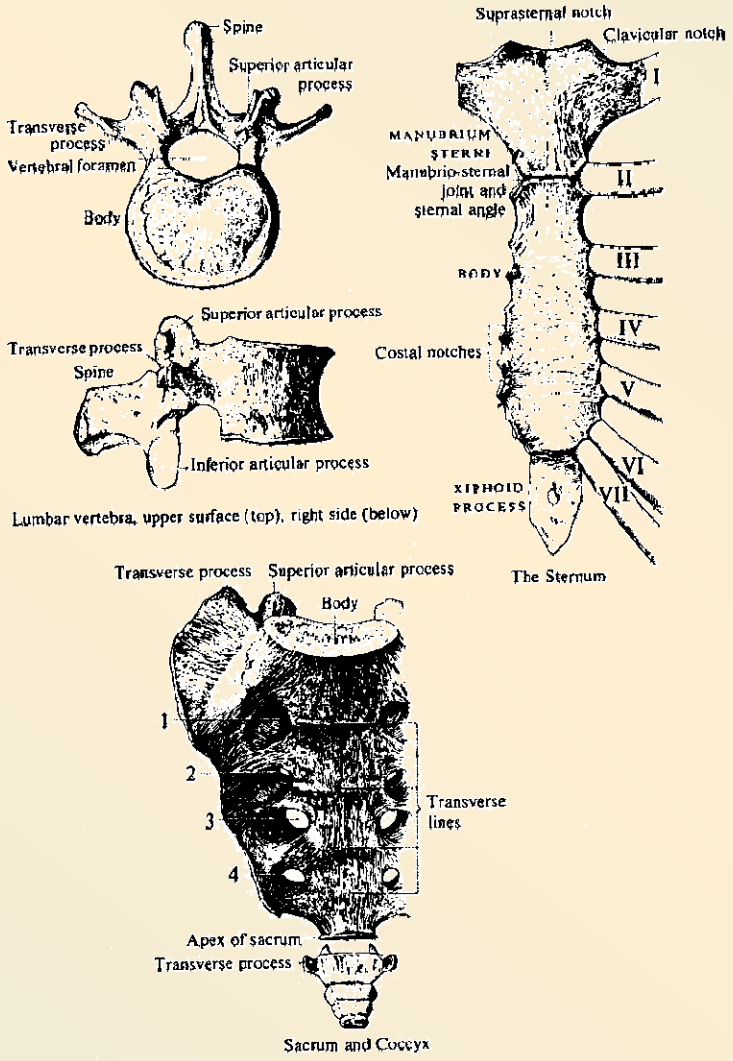

Figure 2.5 Characteristics of the sternum and lower part of the vertebral column.

Ma prima un po' di Anatomia…

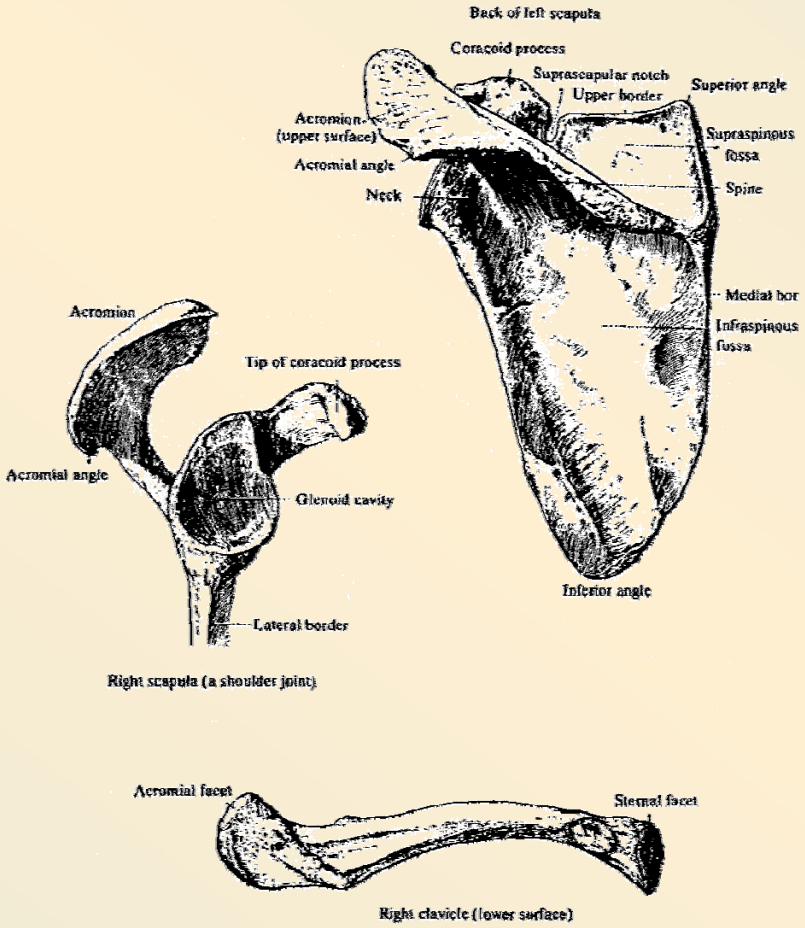

Figure 2.6 Bones of the shoulder girdle

Ma prima un po' di Anatomia…

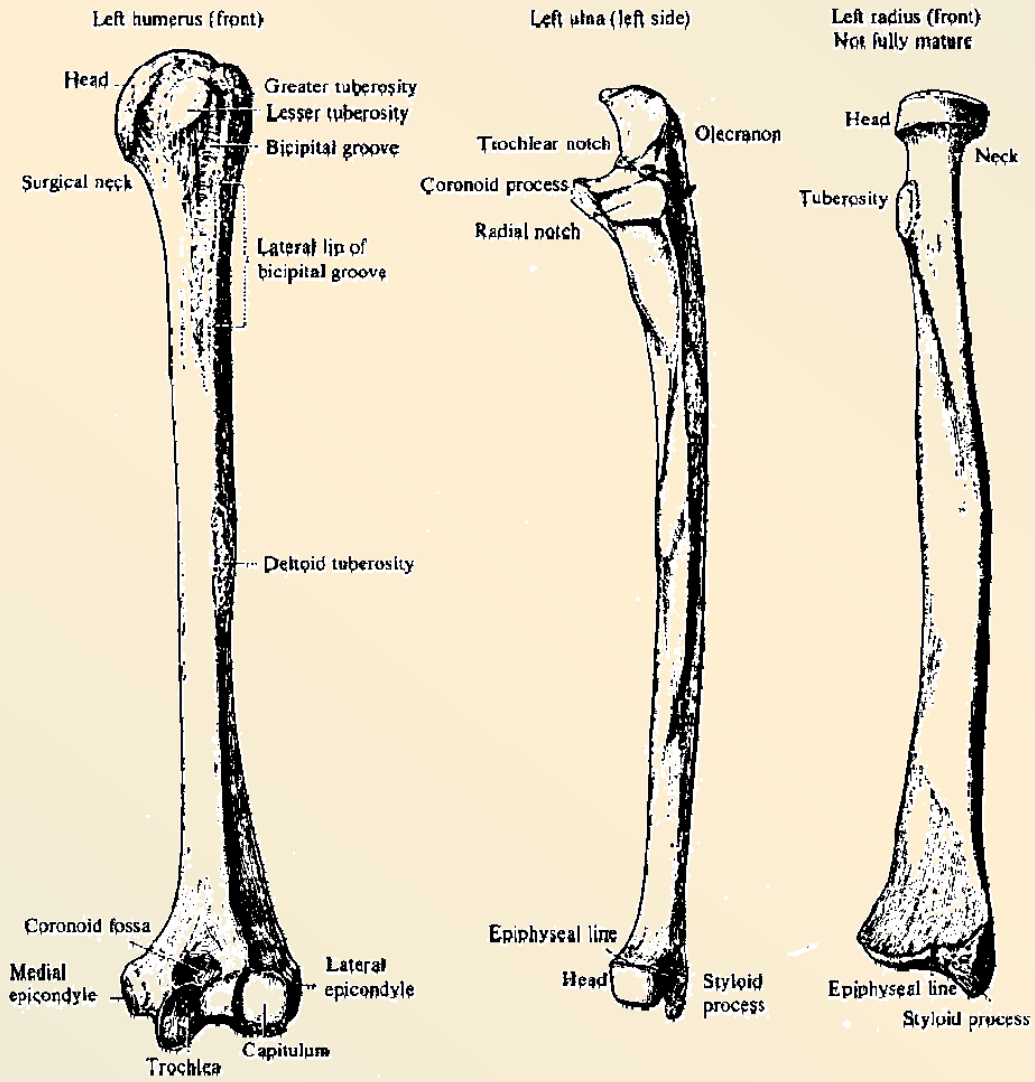

Figure 2.7 Bones of the arm.

Ma prima un po' di Anatomia…

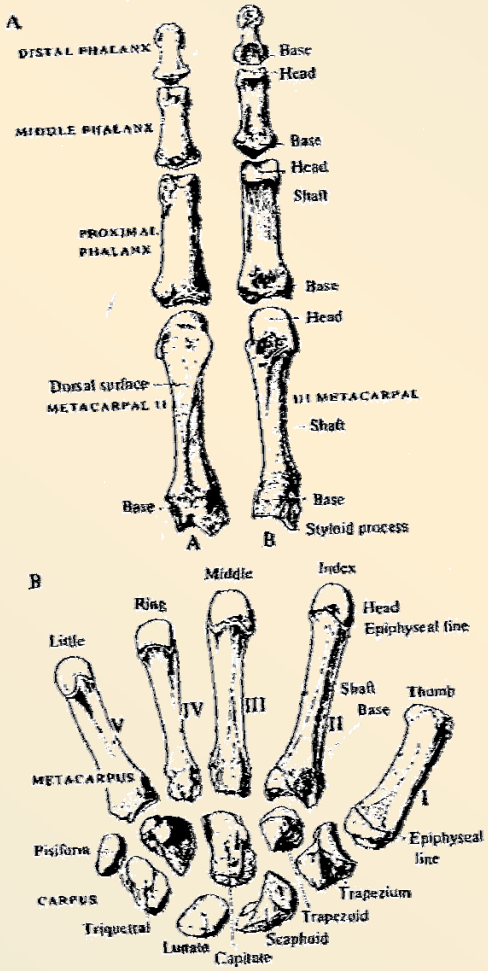

Ma prima un po' di Anatomia…

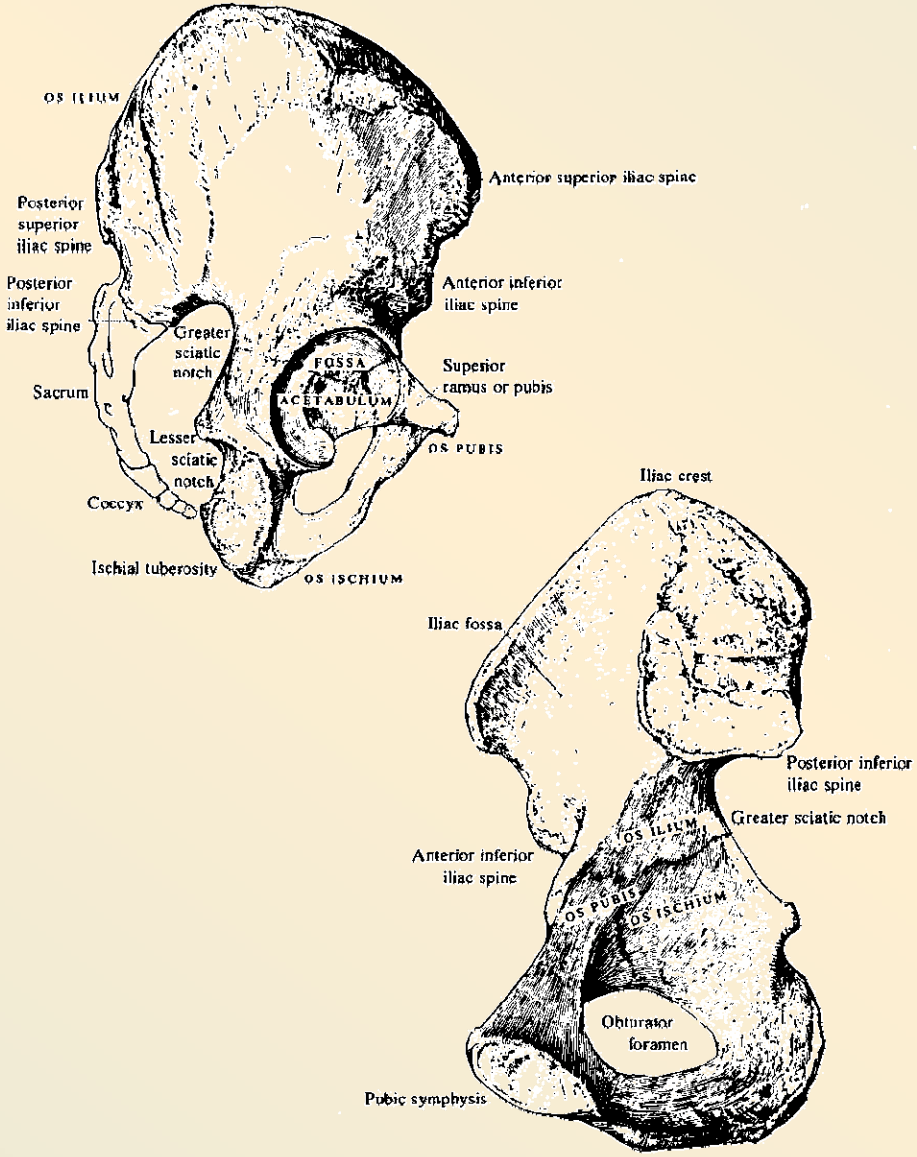

Figure 2.9 Outer and inner views of the right hip bone.

Ma prima un po' di Anatomia…

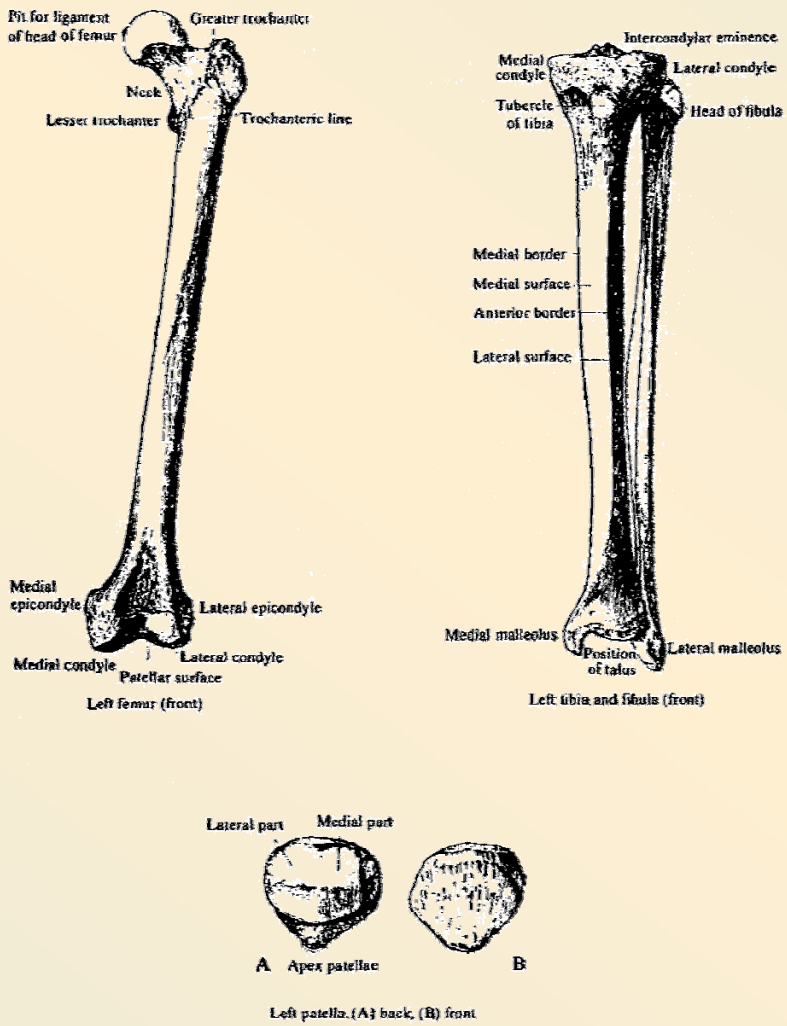

Figure 2.10 Bones of the leg.

Ma prima un po' di Anatomia…

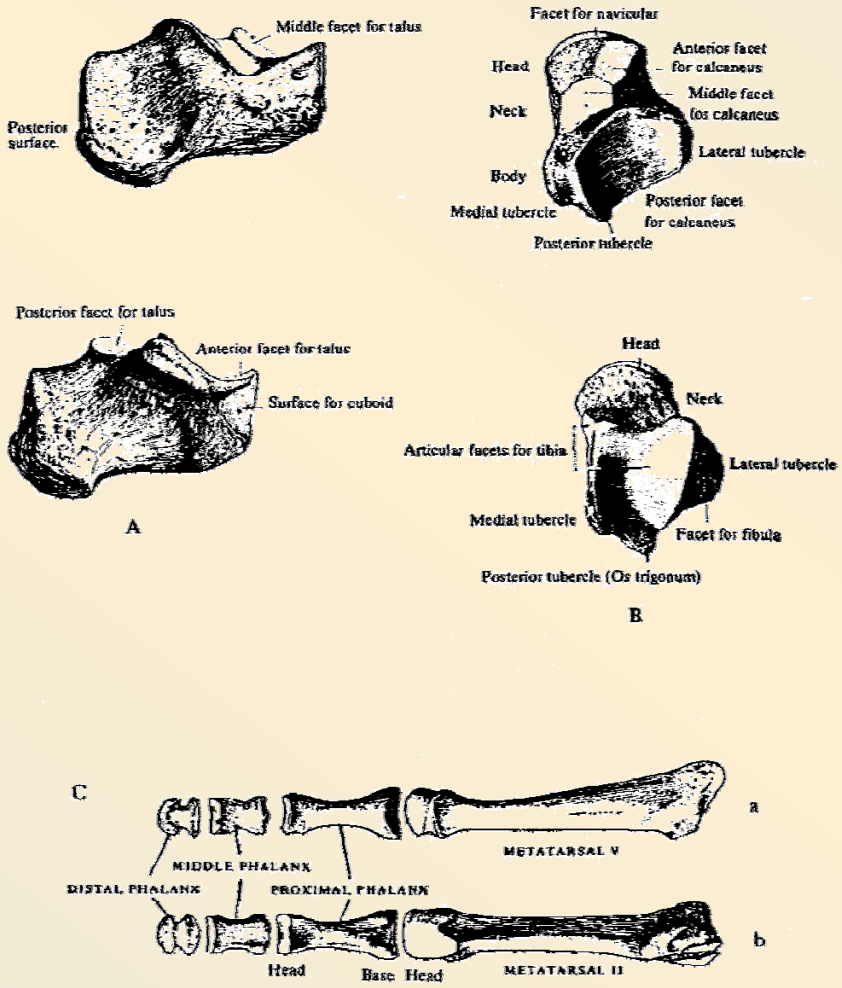

Figure 2.11 Bones of the foot: the left calcaneus and talus. A, lateral (top) and medial (bottom) aspects of the calcaneus. B, lower (top) and upper (bottom) aspects of the talus. C, metatarsals and phalanges. a, upper surface. b, lower surface.

…e qualche Confronto

Figure 2.15a Proximal epiphysis of an immature fossil elephant humerus confused for an early hominid skull.

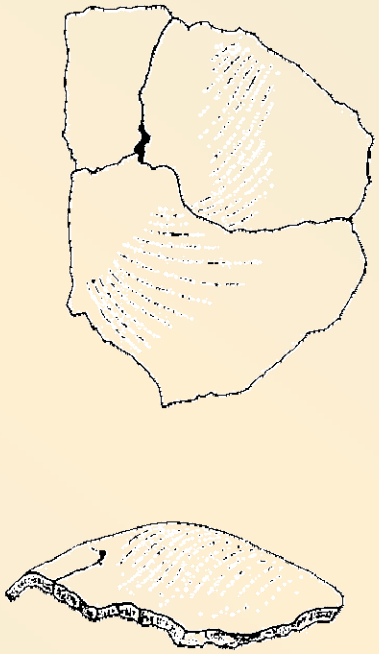

Figure 2.15b Flat bone plate of a turtle confused for a hominid skull.

…e qualche Confronto

Figure 2.16 Human and herbivore incisors.

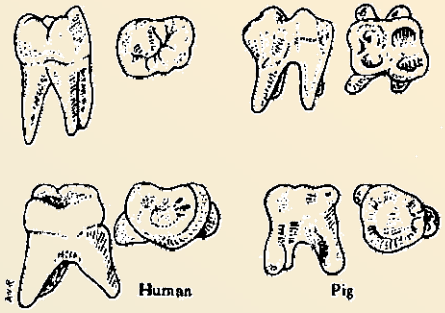

Figure 2.17 Pig and human molar teeth.

…e qualche Confronto

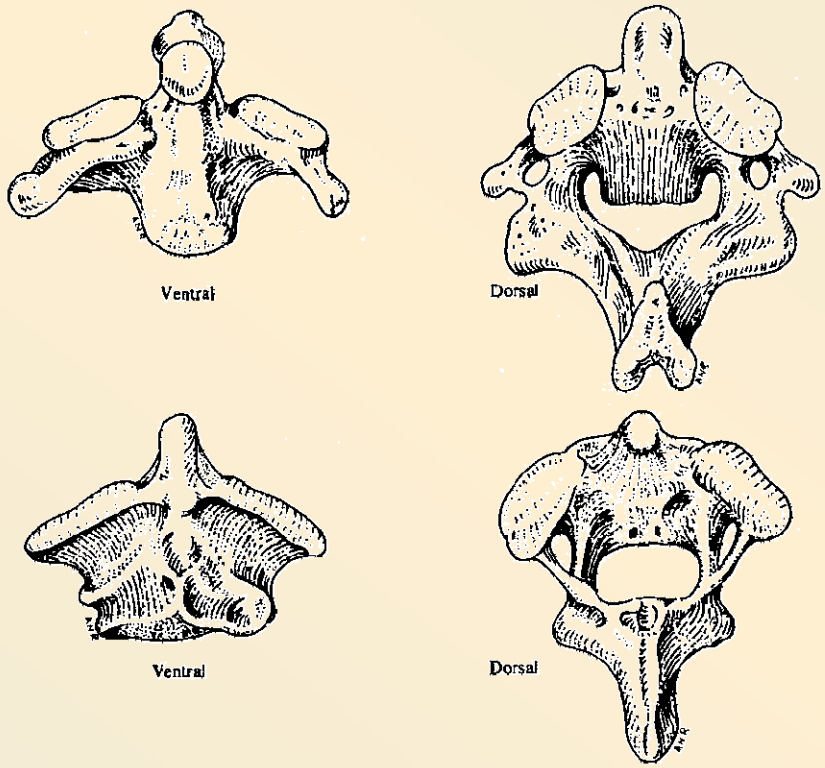

Figure 2.18 Axis vertebrae of a human (above) and wild pig (below).

…e qualche Confronto

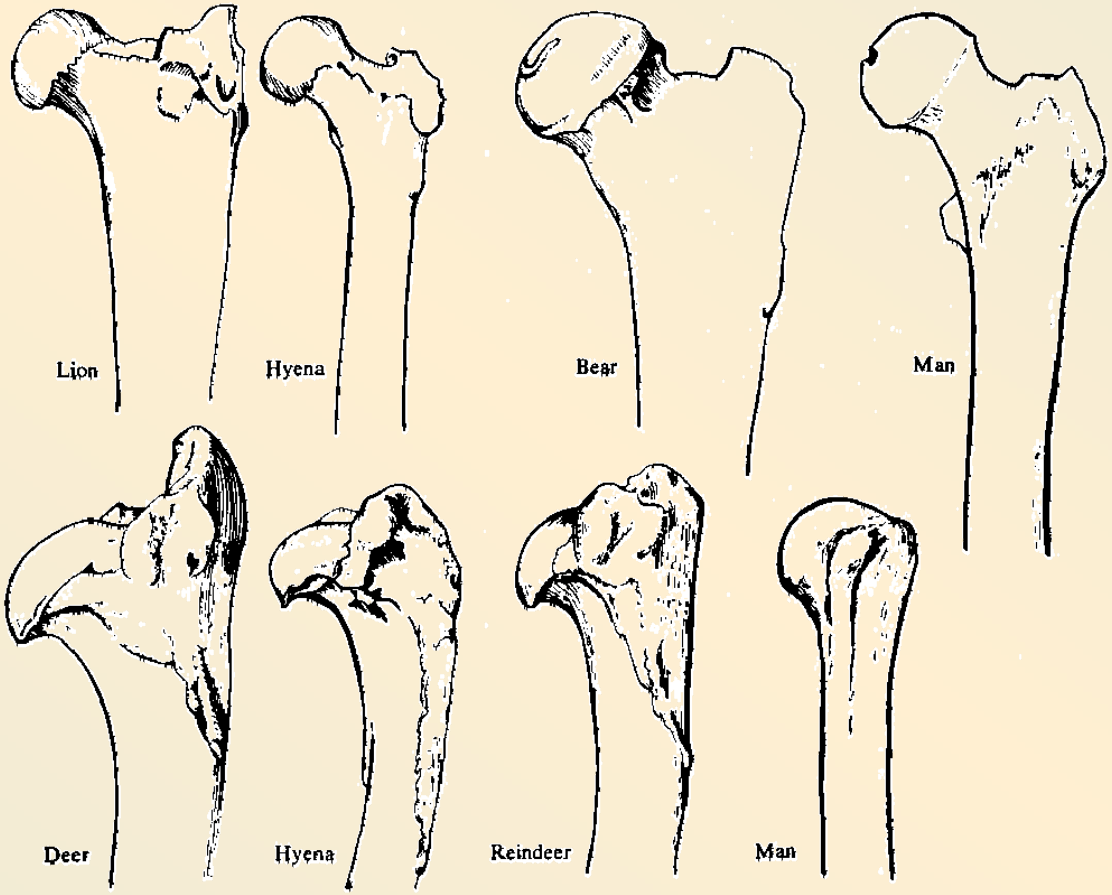

Figure 2.19 Proximal ends of femora (top) and humeri.

…e qualche Confronto

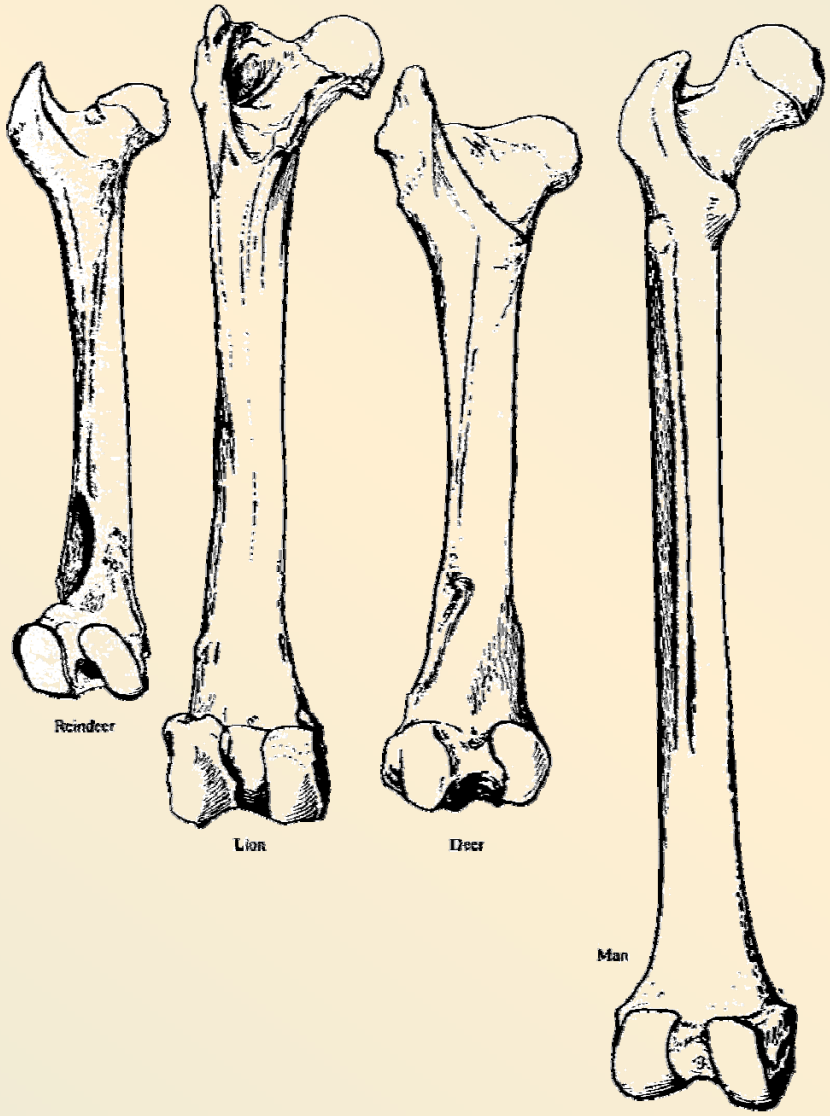

Figure 2.20 Femora from a range of mammals.

…e qualche Confronto

Figure 2.21 Mammalian tibiae.

…e qualche Confronto

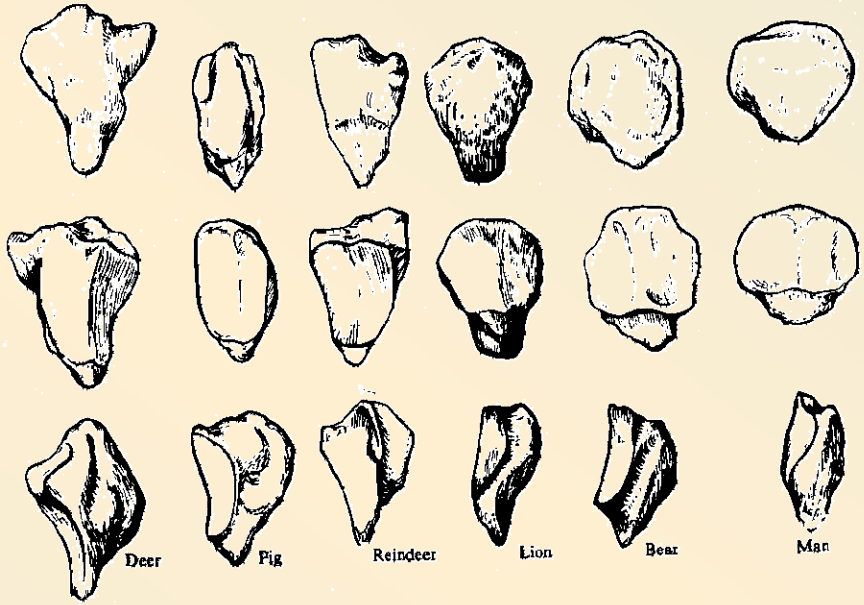

Figure 2.22 Mammalian patellae.

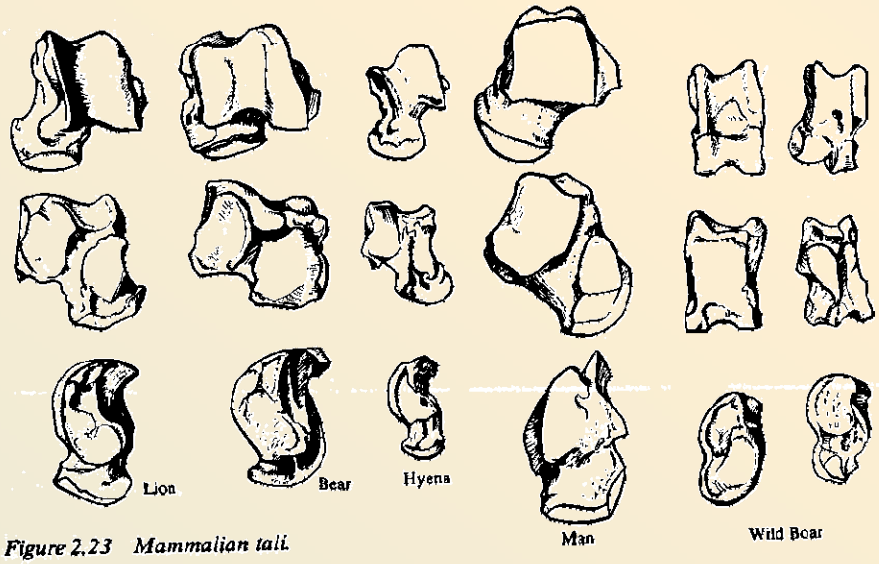

Figure 2.23 Mammalian tali.

…e qualche Confronto

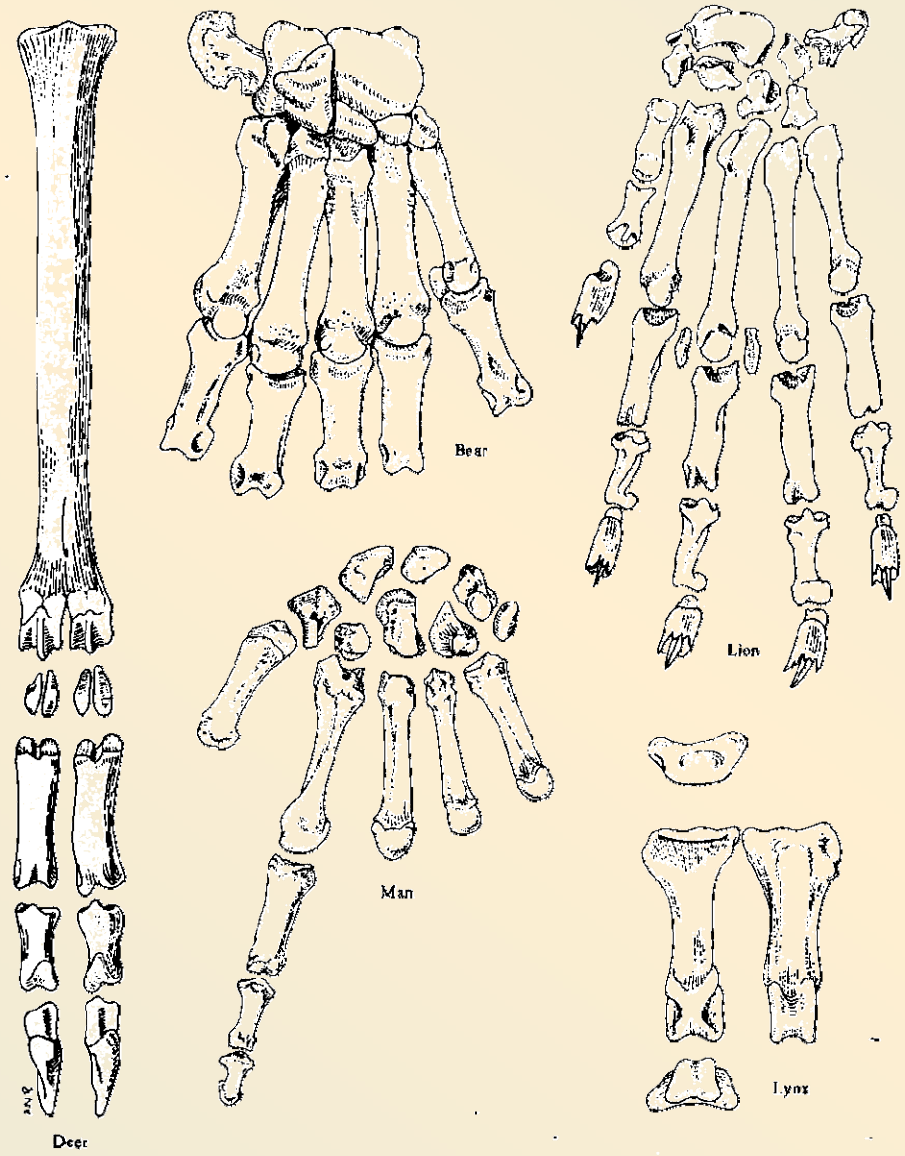

Figure 2.24 Mammalian phalanges, with the Pin Hole Cave phalanx of a lynx at lower right.

Speciale “(orto)Panoramica”

- **Struttura Microscopica:**
  1. **Polpa**
  2. **Dentina Primaria**
  3. **Dentina Secondaria**
  4. **Cemento**
  5. **Cemento Secondario**
  6. **Smalto**

int ↓ **ext**

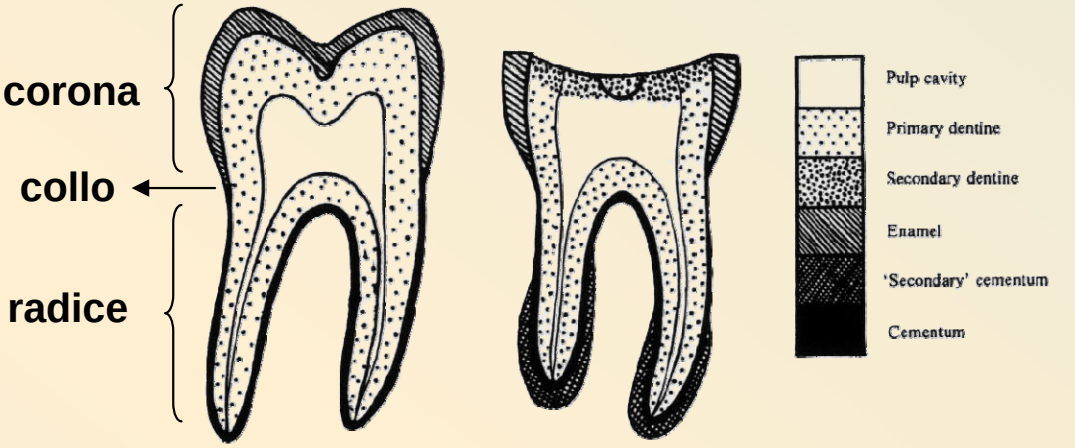

Figure 2.32 Diagrammatic sections through a worn and unworn human molar, showing the various dental tissues.

- **Struttura Macroscopica:**

1. **Radice**
2. **Collo**
3. **Corona**

basso ↓ **alto**

Speciale “(orto)Panoramica”

DENTATURA PROVVISORIA

Right	e	d	c	b	a	a	b	c	d	e	Left part of palate
Right	e	d	c	b	a	a	b	c	d	e	Left part of mandible

a = medial milk incisor
b = lateral milk incisor
c = milk canine
d = first milk molar
e = second milk molar

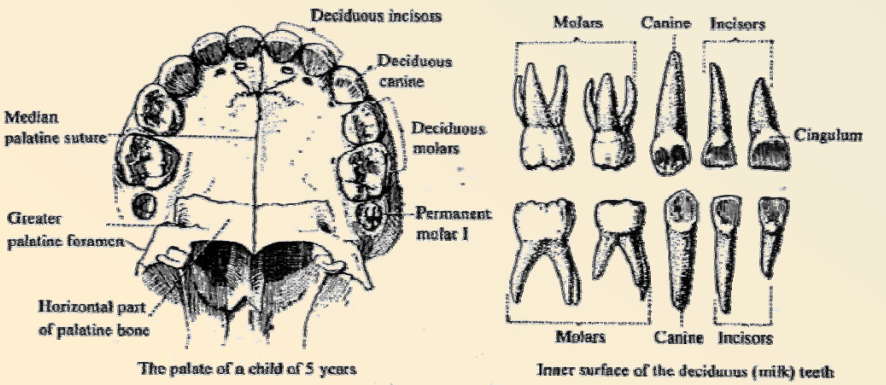

Figure 2.31 The palate of a 5 year old child and the inner surface of deciduous (milk) teeth.

Speciale “(orto)Panoramica”

DENTATURA DEFINITIVA

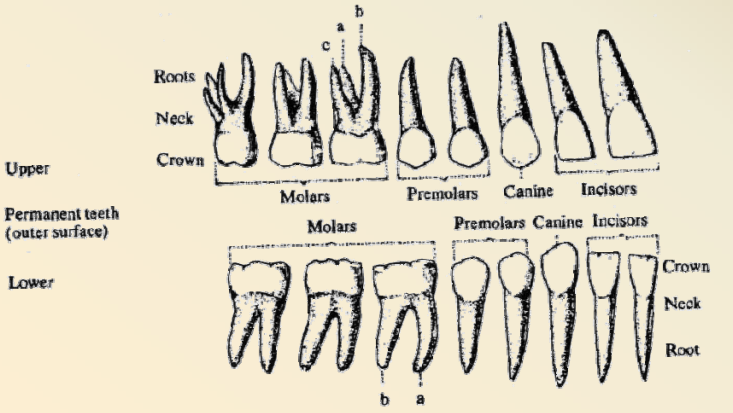

Rt. 8 7 6 5 4 3 2 1	1 2 3 4 5 6 7 8 Lt.	Palate
8 7 6 5 4 3 2 1	1 2 3 4 5 6 7 8	Mandible

The numbers refer to the following teeth:

1 = medial incisor
2 = lateral incisor
3 = canine
4 = anterior premolar
5 = posterior premolar
6 = first or most anterior molar
7 = second molar
8 = third molar or wisdom tooth.

X = tooth missing but socket present
3 = tooth present but socket missing
X = tooth lost ante-mortem
8 = tooth not yet erupted
8 = tooth probably erupting
5 = tooth has a caries cavity
C
6 = tooth displays an abscess at the root.
A

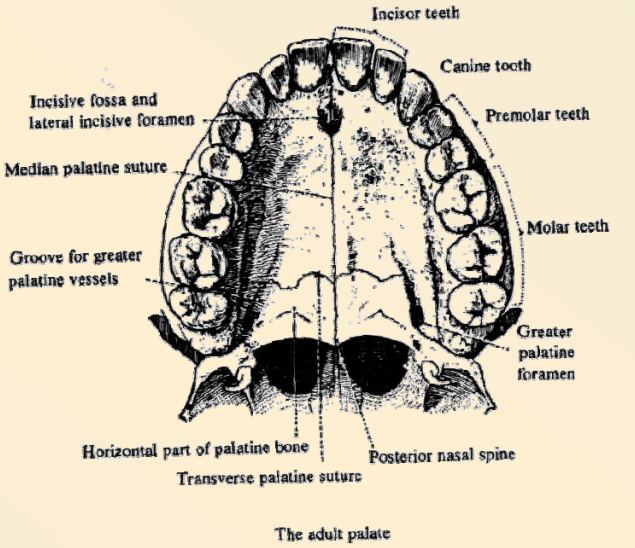

Figure 2.28 Human teeth and the adult palate.

La “Carta d’Identità”

DETERMINARE IL SESSO

- **Cranio ♂:**
  - **Più largo e pesante**
  - **Rilievi più marcati**
  - **Tratti più “squadrati”**
  - **Palato e denti più larghi**
- **Pelvi ♂:**
  - **Più robusta**
  - **Acetabolo più grande**
  - **Solchi muscolari più marcati**
  - **Grande incisura più stretta**
  - **Solco pre-auricolare inesistente**

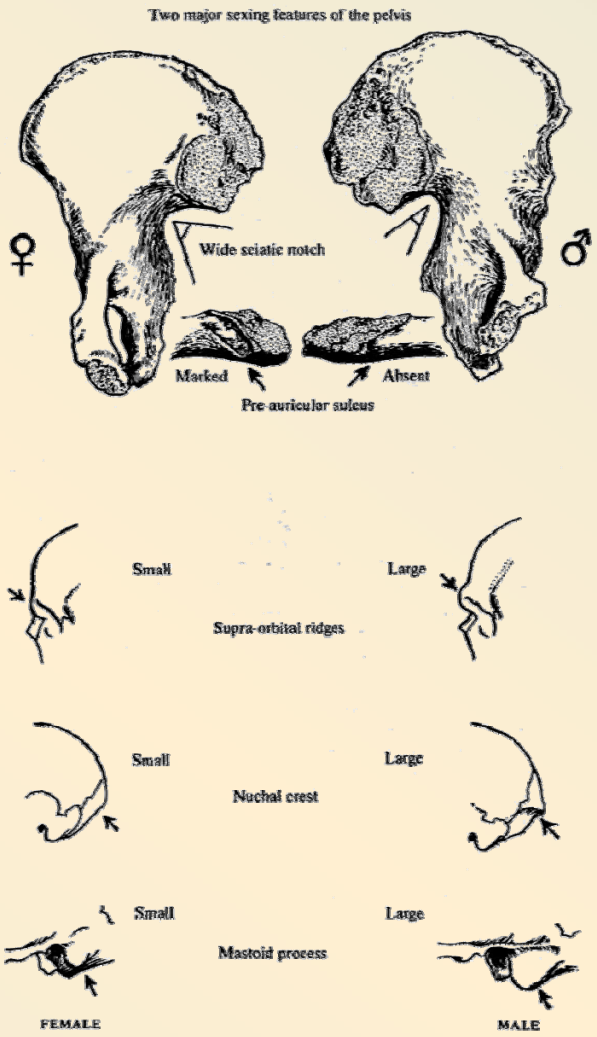

Figure 3.1 Principal sexing features of the pelvis and skull.

La “Carta d’Identità”

DETERMINARE IL SESSO

- **Colonna Vertebrale ♂:**
  - **Più grande**
  - **Processi e rilievi marcati**
  - **Atlante massiccio**
  - **Sacro lungo e stretto**
- **Sterno, Clavicola e Scapola ♂:**

  più lunghe, robuste e spesse, rilievi muscolari più marcati

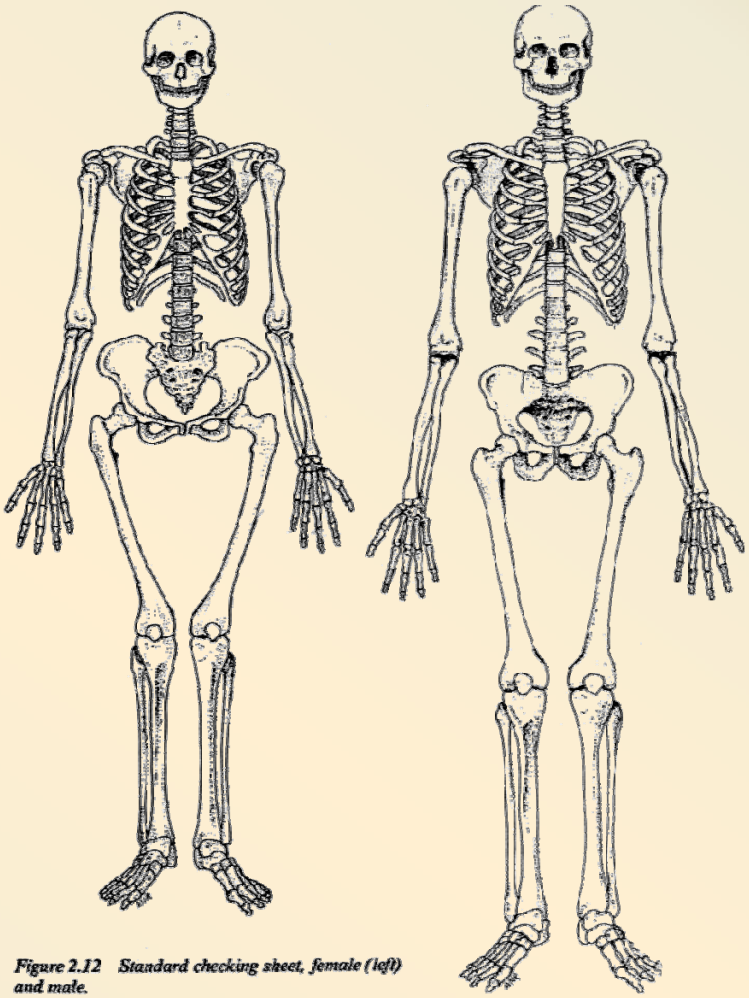

Figure 2.12 Standard checking sheet, female (left) and male.

La “Carta d’Identità”

DETERMINARE L’ETA’

- **Cranio:**
  - **Saldatura suture**
  - **Grado di dentizione**
  - **Grado di consunzione superficie occludente denti (molari)**

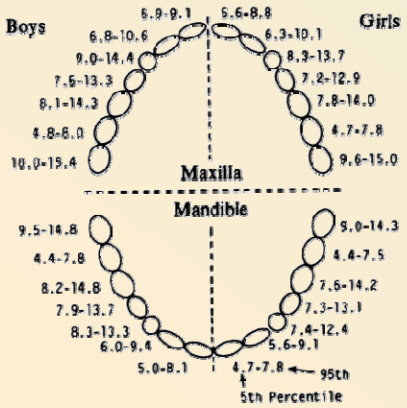

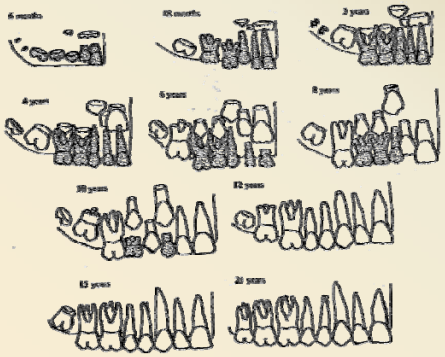

Figure 3.34. Average developmental stages of the human dentition from 6 months of age to 21 years. Stippled teeth represent the milk (deciduous) dentition.

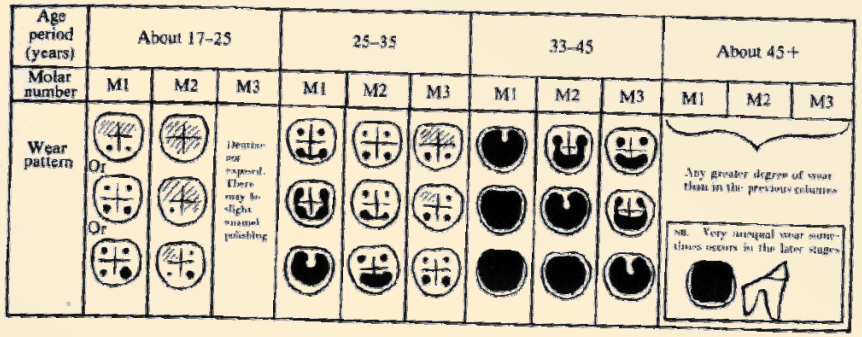

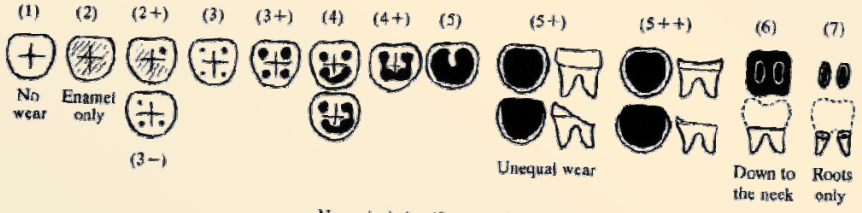

Numerical classification of molar wear
(N.B. Some patterns are more common than others, and there are minor differences between upper and lower dentitions.)

La “Carta d’Identità”

DETERMINARE L’ETA’

- **Scheletro Assile:**
  - **Saldatura cartilagini epifisarie (stress accrescitivi tra 0 e 6 anni rilevabili all’epifisi tibiale distale)**
  - **Grado di rugosità rilievi sinfisi pubica**

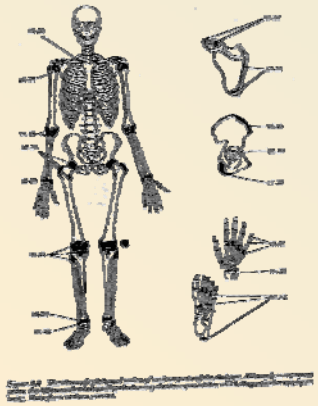

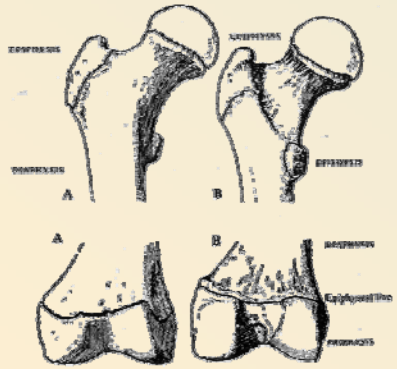

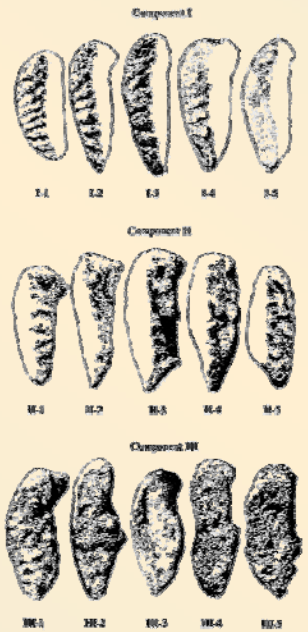

Table Ia
Age limits of the component stages

Stage	Age Range	Mode
Component I		
0	17.0–18.0	17.0
1	18.0–21.0	18.0
2	18.0–21.0	19.0
3	18.0–24.0	20.0
4	19.0–29.0	23.0
5	23.0 +	31.0
Component II		
0	17.0–22.0	19.0
1	19.0–23.0	20.0
2	19.0–24.0	22.0
3	21.0–28.0	23.0
4	22.0–33.0	26.0
5	24.0 +	32.0
Component III		
0	17.0–24.0	19.0
1	21.0–28.0	23.0
2	24.0–32.0	27.0
3	24.0–39.0	28.0
4	29.0 +	25.0
5	38.0 +	

Figure 3.7 Age changes at the pubic symphysis. The five stages of the three components are given as described in the text.

La “Carta d’Identità”

DETERMINARE L’ALTEZZA:

Applicazione delle formule nella tabella a fianco

(Data by Trotter & Gleser, 1952, 1958)

Males	Females
White	*White*
1.31 (Fem + Fib) + 63.05	0.68 Hum + 1.17 Fem + 1.15 Tib + 50.12
1.26 (Feb + Tib) + 67.09	1.39 (Fem + Tib) + 53.20
2.60 Fib + 75.50	2.93 Fib + 59.61
2.32 Fem + 65.53	2.90 Tib + 61.53
2.42 Tib + 81.93	1.35 Hum + 1.95 Tib + 52.77
1.82 (Hum + Rad) + 67.97	2.47 Fem + 54.10
1.78 (Hum + Ulna) + 66.98	4.74 Rad + 54.93
2.89 Hum + 78.10	4.27 Ulna + 57.76
3.79 Rad + 79.42	3.36 Hum + 57.97
3.76 Ulna + 75.55	
Negro	*Negro*
1.20 (Fem + Fib) + 67.77	0.44 Hum − 0.20 Rad + 1.46 Fem + 0.86 Tib + 56.33
1.15 (Feb + Tib) + 71.75	1.53 Fem + 0.96 Tib + 58.54
2.10 Fem + 72.22	2.28 Fem + 59.76
2.19 Tib + 85.36	1.08 Hum + 1.79 Tib + 62.80
2.34 Fib + 80.07	2.45 Tib + 72.65
1.66 (Hum + Rad) + 73.08	2.49 Fib + 70.90
1.65 (Hum + Ulna) + 70.67	3.08 Hum + 64.67
2.88 Hum + 75.48	3.31 Ulna + 75.38
3.32 Rad + 85.43	3.67 Rad + 71.79
3.20 Ulna + 82.77	
Mongoloid	
1.22 (Fem + Fib) + 70.24	
1.22 (Feb + Tib) + 70.37	
2.40 Fib + 80.56	
2.39 Tib + 81.45	
2.15 Fem + 72.57	
1.68 (Hum + Ulna) + 71.18	
1.67 (Hum + Rad) + 74.83	
2.68 Hum + 83.19	
3.54 Rad + 82.00	
3.48 Ulna + 77.45	

Misure Fondamentali

PUNTI CRANIOMETRICI:

- ***Bregma*: sutura coronale - sagittale**
- ***Lambda*: sutura sagittale - lambdoidea**
- ***Asterion*: sutura temporale - parietale - occipitale**
- ***Pterion*: sutura frontale - temporale - parietale**
- ***Gonion*: corpo – branca montante mandibola**

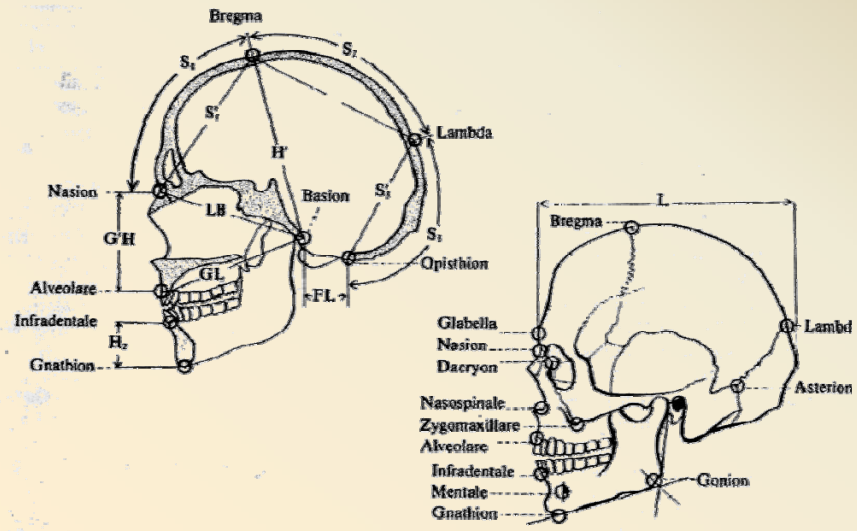

Figure 4.2 The principal craniometric points of the skull.

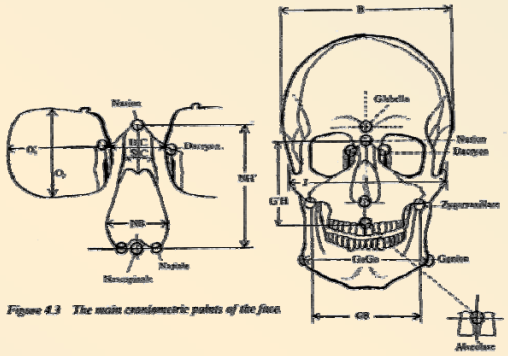

Figure 4.3 The main craniometric points of the face.

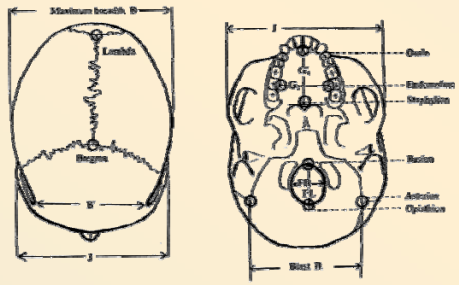

Figure 4.4 Other craniometric points of the vault and skull base.

Misure Fondamentali

MISURE CRANIOMETRICHE:

cfr. tabella a fianco

Description of measurement	*Biometric symbol**
I. Maximum cranial length. Greatest length in median sagittal plane from glabella to the most posterior point on the occipital. (Spreading calliper.)	L
II. Maximum Breadth. Greatest bi-parietal breadth, taken at right angles to the mid-sagittal plane. (Spreading calliper.)	B
III. Basi-bregmatic height. From the basion to the bregma. (Spreading calliper.)	H'
IV. Basi-nasal length. From the basion to the nasion. (Sliding calliper.)	LB
V. Basi-alveloar length. From the basion to the alveolare. (Sliding calliper.)	GL
VI. Upper facial height. From the nasion to the alveolare. (Sliding calliper.)	G'H
VII. Bimaxillary breadth. From one zygomaxillare to the other. (Small sliding calliper.)	GB
VIII. Bizygomatic breadth. Greatest breadth between zygomatic arches. (Spreading or sliding calliper.)	J
IX. Nasal height. From nasion to nasospinale. (Small sliding calliper.)	NH'
X. Nasal breadth. The maximum breadth of the nasal (pyriform) aperture between the anterior surfaces of its lateral margins; perpendicular to the mid-sagittal plane. (Small sliding calliper.)	NB
XI. Orbital breadth. Greatest breadth of the orbit measured from the dacryon to the anterior surface of its lateral margin. (Small sliding calliper.)	O'_1 (left or right)
XIII. Palatal length. From the staphylion to the orale. (Small sliding calliper.)	G'_1
XIV. Palatal breadth. From one endomolare to the other. (Small sliding calliper.)	G_2

*This is not the symbol used by Howells (1973), but is the British equivalent.

Misure Fondamentali

MISURE OSSA LUNGHE:

- ***Femore*: testa - condilo mediale**
- ***Tibia*: piatto med. - malleolo med.**
- ***Perone*: estremità dist - prox.**
- ***Omero*: testa - troclea med.**
- ***Radio*: testa - proc. stiloideo**
- ***Ulna*: olecrano – proc. stiloideo**

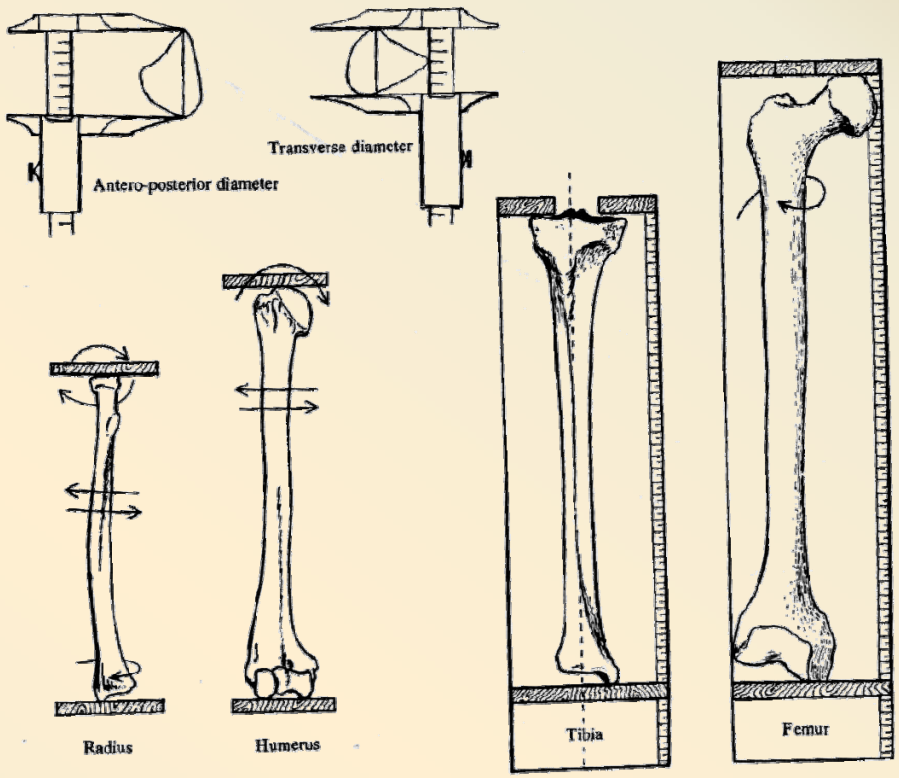

Figure 4.8 The positioning of long-bones in order to record maximum lengths. Horizontal arrows denote movement from side to side. Curved arrows denote circular movement. The broken line shows the axis of the long-bone parallel to that of the osteometric board. Also the procedure for taking the upper tibial shaft dimensions.

Varianti Anatomiche

- **“Tori”: protuberanze ossee mascellari, mandibolari, uditive e palatine**

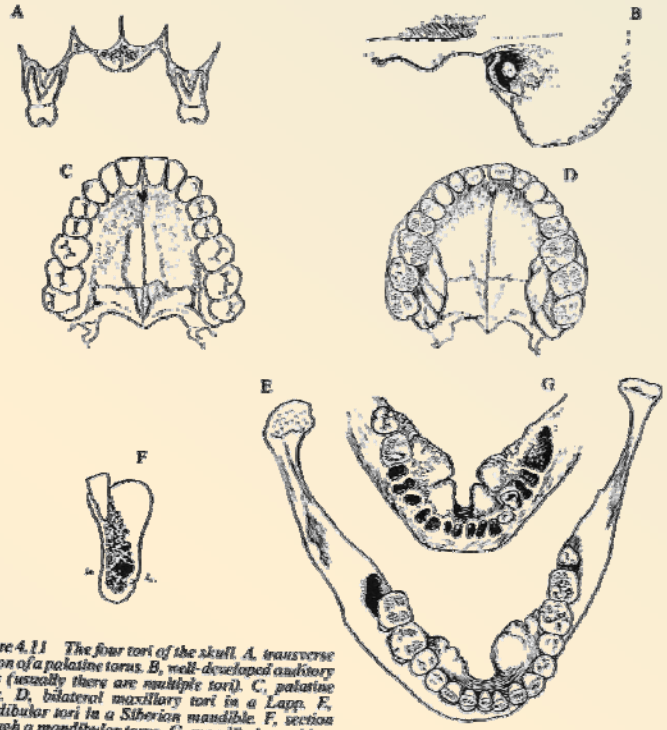

Figure 4.11 The four tori of the skull. A, transverse section of a palatine torus. B, well-developed auditory torus (usually there are multiple tori). C, palatine torus. D, bilateral maxillary tori in a Lapp. E, mandibular tori in a Siberian mandible. F, section through a mandibular torus. G, mandibular tori in a Lapp. D, E, G, after Van Den Broek.

Varianti Anatomiche

- **Varianti di Femore, Talo, Atlante**

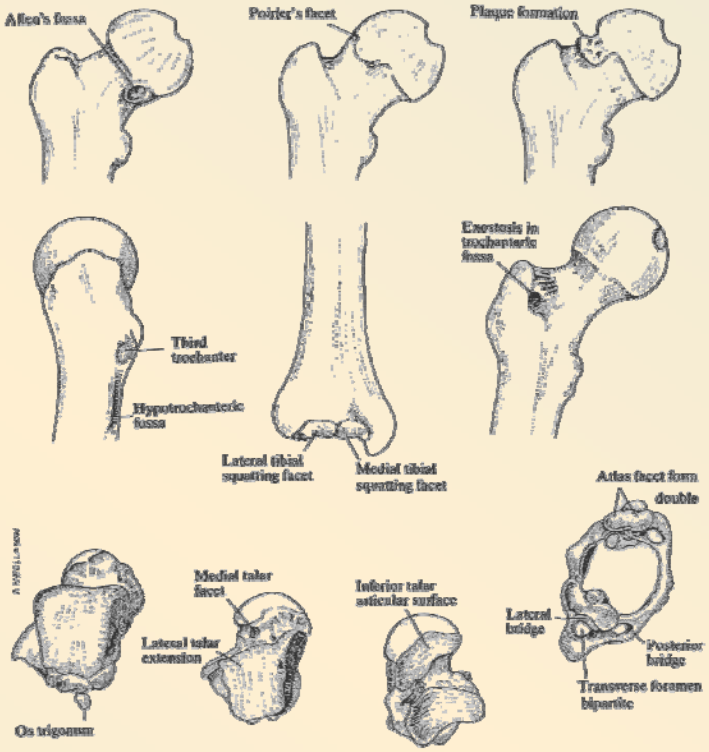

Figure 4.13 Variation in the post-crunial skeleton (after Finnegan, 1978).

Varianti Anatomiche

- **Varianti di Calcagno, Rotula, Scapola ed Anca**

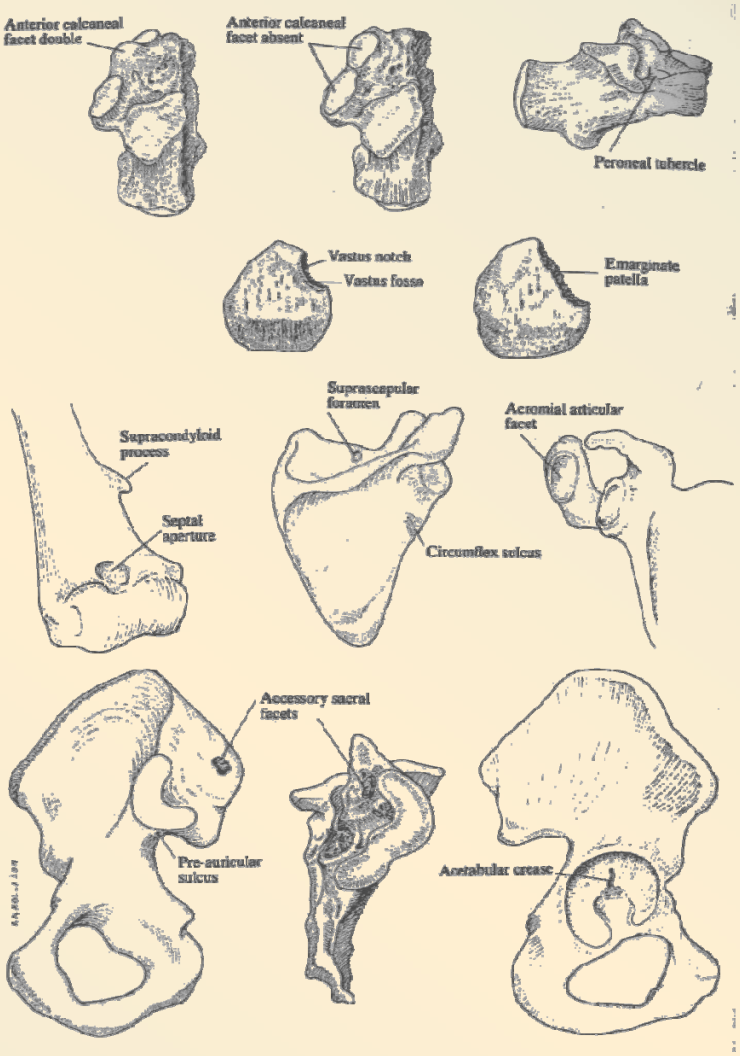

Varianti Anatomiche

- **Altre varianti scheletriche con relative % di rinvenimento sui reperti**

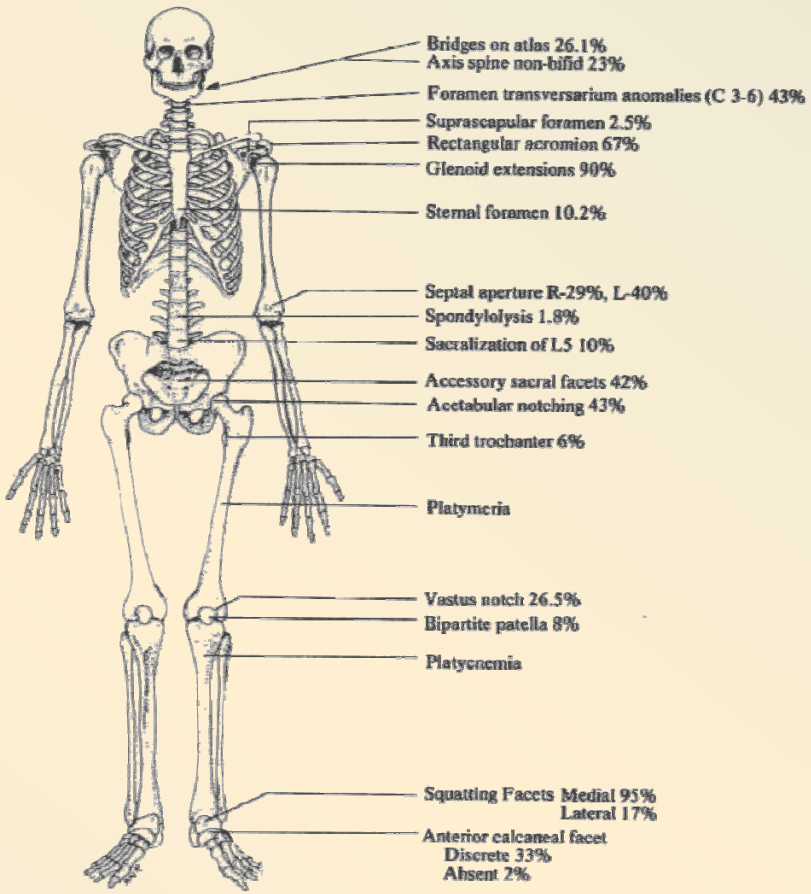

Figure 4.12 Infracranial variation in the skeletons from Fairty, Canada (Anderson, 1964).

Varianti Dentali

- **Errati posizionamenti ed accavallamenti**

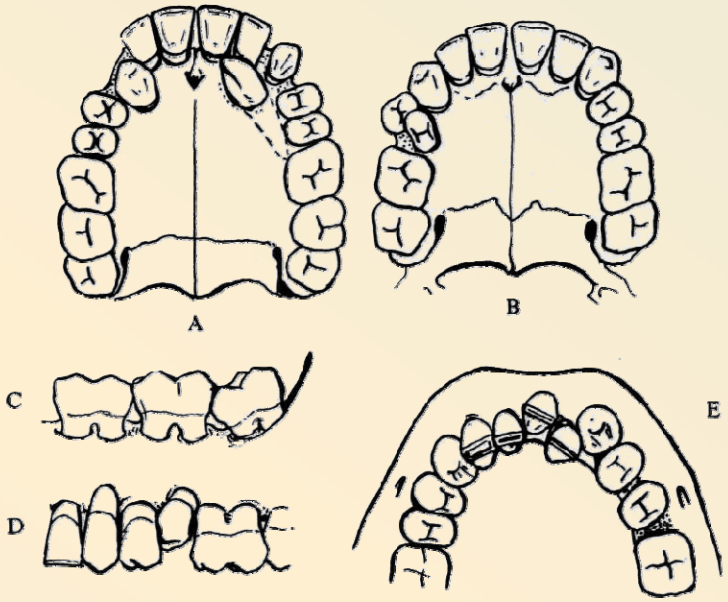

Figure 2.29 Anomalous positions of teeth. A, Malpositioned upper canines, with the retention of the milk canine on the right. B, Irregularly placed and rotated premolars on the left of the palate. C, Impacted third molar. D, Impacted second premolar. E, Crowding and rotation of the anterior teeth to the right of the jaw.

Varianti Dentali

- **Chiusura della bocca con errata occlusione dentale**

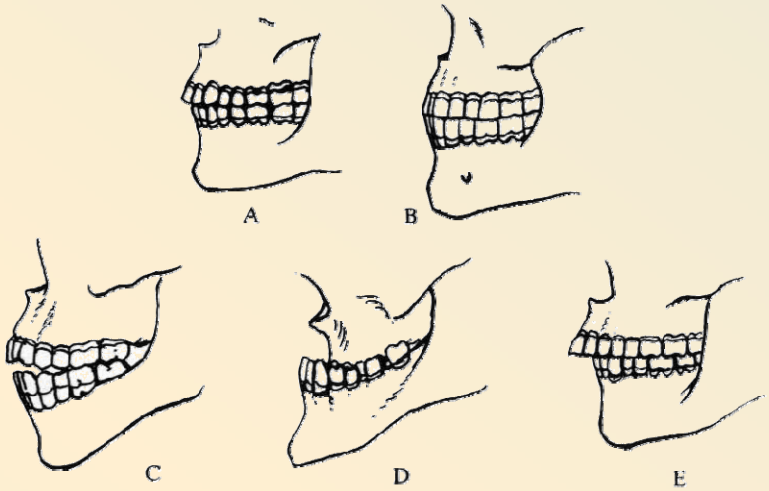

Figure 2.30 Various types of dental occlusion to be seen in man. A, Most common with slight overlap of the upper anterior teeth over the lower ones. B, Edge-to-edge bite of the anterior teeth. C, Anterior open bite (rare). D, Extreme protrusion of the lower jaw and teeth. E, Marked overjet of the upper anterior teeth.

Varianti Dentali

- **Presenza di denti soprannumerari per mancata sostituzione dentatura provvisoria -> definitiva 1**

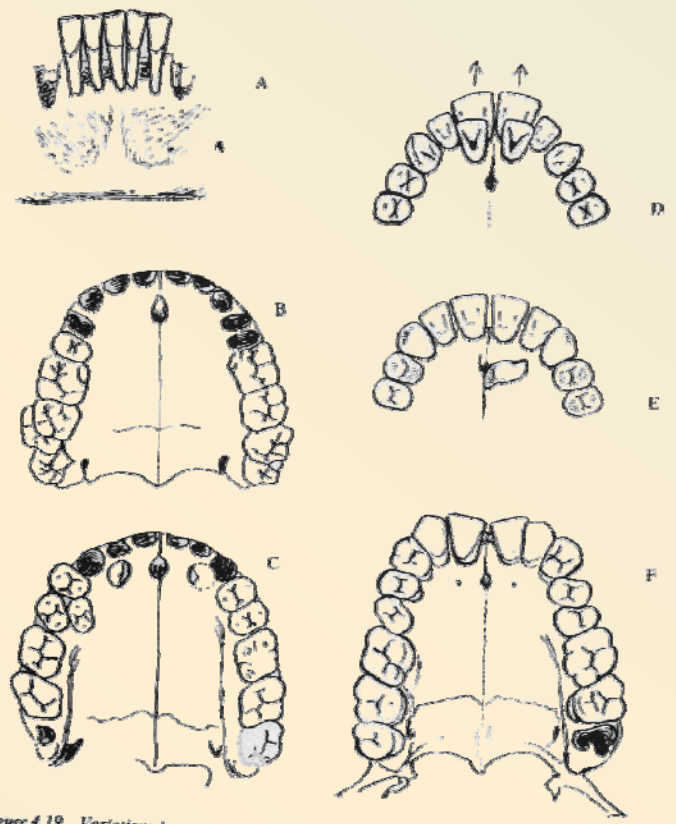

Figure 4.19 Variations in extra (supernumerary) teeth. A, presence of five incisors in a mandible from Thames deposits. B, bilateral occurrence of fourth molars in an Ashanti. C. Nigerian female specimen with an extra premolar and bilateral supernumeraries buried within the palate. D, additional medial incisors in a Prona Indian. E, pre medieval British case of a non-specific medial supernumerary tooth on the surface of the palate. F, presence of extra premolars and absence of canines in a Nepalese specimen.

Varianti Dentali

- **Presenza di denti soprannumerari per mancata sostituzione dentatura provvisoria -> definitiva 2**

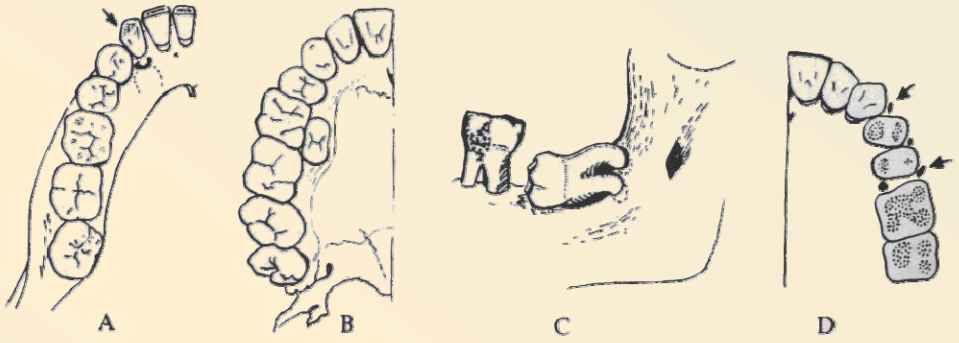

Figure 4.20 A, retention of a milk canine into adult life, with the development but retention of the permanent canine within the jaw. Bronze Age specimen from Dorset. B, retention of a milk molar and eruption of the permanent 2nd premolar to one side of it. Andamanese. C, early British case of horizontally positioned third molar. D, retention of the roots of milk teeth by the side of permanent teeth in a Guanche.

Varianti Dentali

- **Variazioni di forma (*riduzione, ripiegamento, malformazione corona, doppia radice, fusione, “perla“ di smalto, taurodontismo, extra cuspide*)**

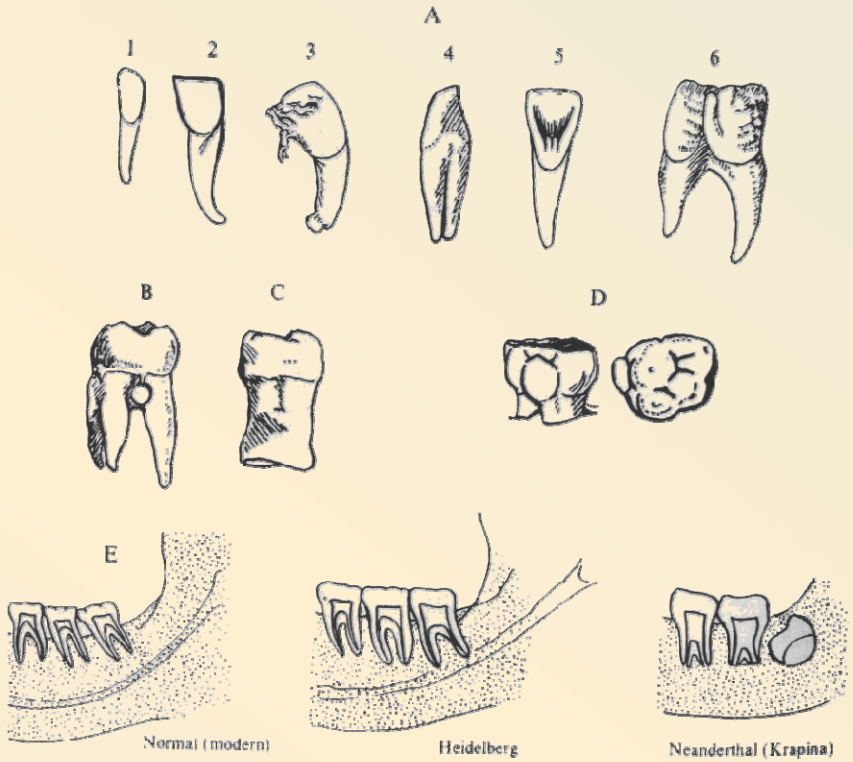

Figure 4.21 A, variations in the form of the anterior teeth. 1, very reduced incisor; 2, incisor with very curved root; 3, incisor with malformed crown; 4, canine with two roots; 5, an incisor with a markedly shovel-shaped crown; 6, fused anterior teeth. B, molar with enamel 'pearl' at roots. C, an extreme case of taurodontism. D, well-defined extra cusp on molar. E, radiographic appearance of normal and taurodont teeth.

Varianti non proprio “Anatomiche”

- **Distorsione indotta della Volta Cranica e del Tarso – Metatarso per ragioni culturali**

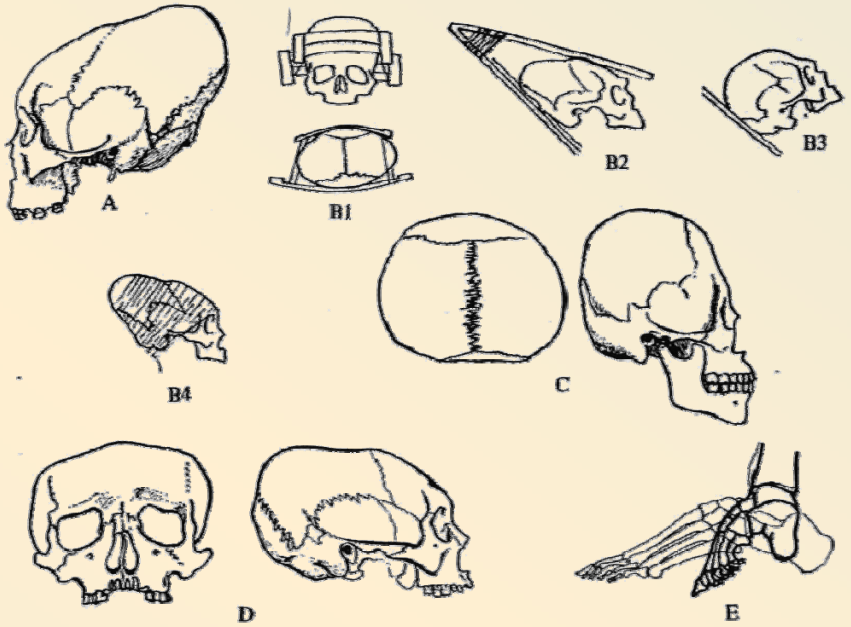

Figure 2.27 Cultural deformation. A, Kwakiutl skull from British Columbia with vault deformity through binding. B, Methods of producing vault deformity: 1, antero-posterior compression. 2, special cradling device (Chinook). 3, occipital flattening. 4, binding. C, Top and lateral views of a Mexican skull showing antero-posterior flattening. D, Lateral and facial views of a skull showing deformity due to vertical compression. E, Skeleton of a deformed Chinese foot superimposed on normal foot bones.

Varianti non proprio “Anatomiche”

- **Lavorazione dei Denti con scalpelli e punte sottili**

A Variations in the form of artificially mutilated teeth. From various parts of the world.



Varianti non proprio “Anatomiche”

- **Fissurazioni Volute e Ferite Accidentali**

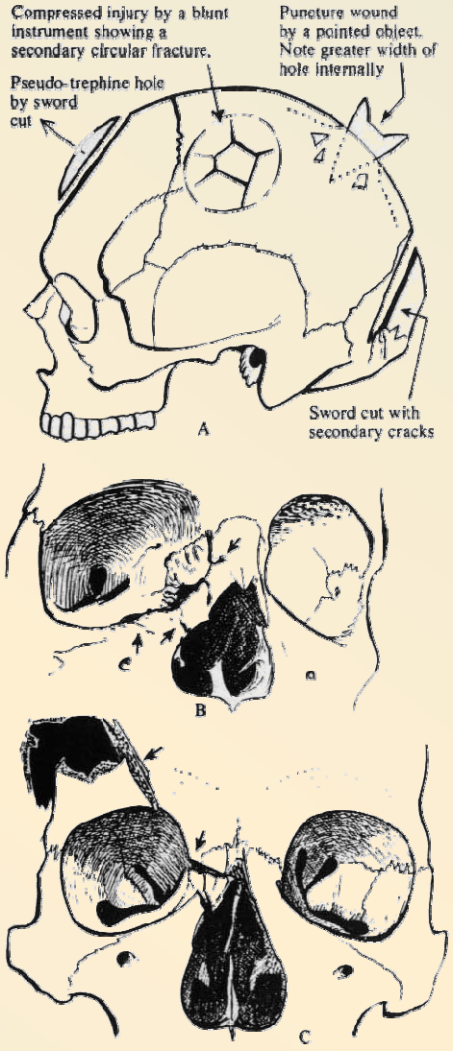

Figure 5.1 A, Variations in the type of cranial injury. B, Injury to the orbital and nasal regions, showing considerable healing. Gaboon male [1864.67.36]. C, Injury to the face received just before death, showing the clear-cut unhealed nature of the wounds. Nigerian female [AF 1822].

Varianti non proprio “Anatomiche”

- **Scultura del Cranio (p. m.)**

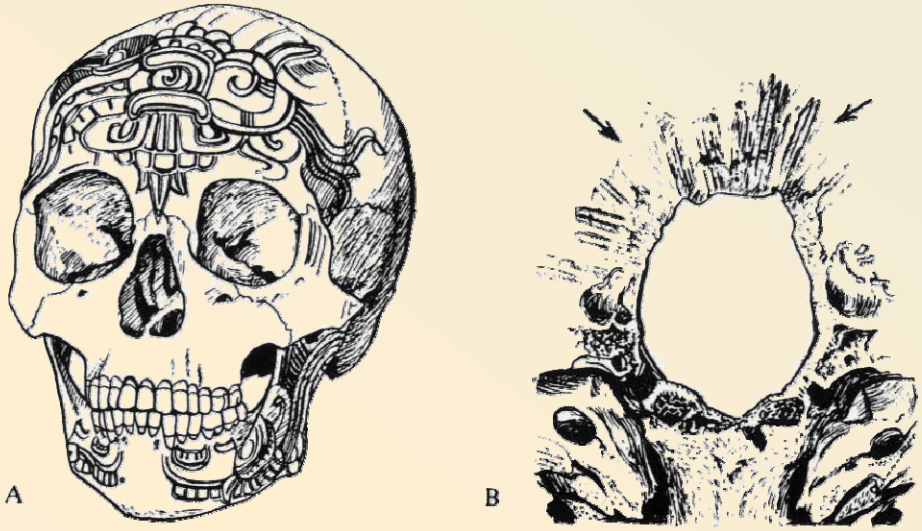

Figure 5.2 Decorated skulls, Guatemala

Varianti non proprio “Anatomiche”

- **Riadattamento (macabro) di Volte Craniche a “Coppe” per bere**

Figure 5.3 A. A prehistoric example of a skull used as a container. B. A modern example, probably from Africa.

Varianti non proprio “Anatomiche”

- **Trapanazione e Scalfitura Calotta Cranica (*Religione? Magia? Medicina? Cultura? Moda?)***

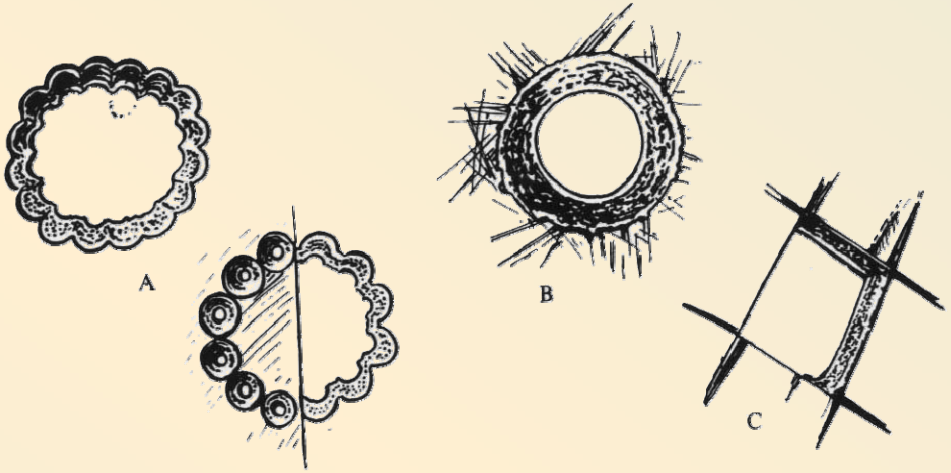

Figure 5.5 Types of trephine hole. A, By drilling holes and cutting through the divisions between them. B, By slowly cutting out a roundel with a metal or flint tool. C, By four deep incisions which enclose a rectangular area of bone.

Varianti non proprio “Anatomiche”

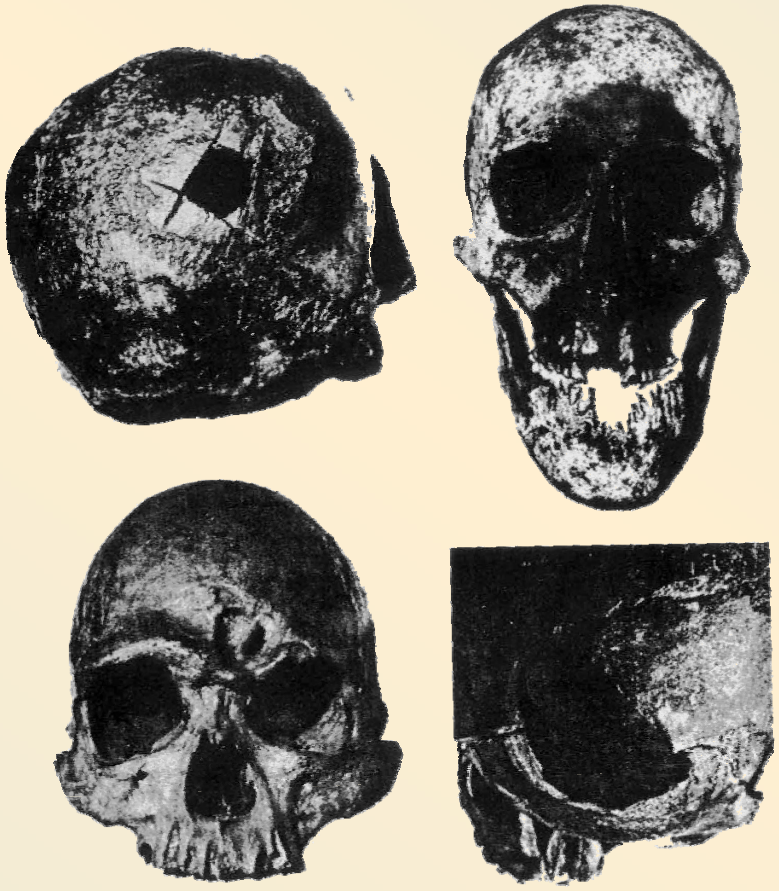

Plate 5.1 A. Posterior aspect of a skull from Lachish, Palestine, displaying the rectangular type of trephine hole. B. Skull from New Ireland with healed frontal trephine. C. Facial view of a female skull believed to be of an Ancient Egyptian, showing considerable facial lenthening, possibly caused by acromegaly. D. The frontal region of a skull from the Stanwick Fortifications with a sword injury simulating trephinaion.

Malattie “Ossee”

- **Infiammazioni:**
  - **Osteiti:**
    - **Periostiti**
    - **Osteomieliti**
  - **Tubercolosi**
  - **Treponematosi:**
    - **Pinta**
    - **Frambesia**
    - **Sifilide Endemica**
    - **Sifilide Venerea**
  - **Lebbra**
- **Tumori:**
  - **Benigni:**
    - **Osteoma**
  - **Maligni:**
    - **Osteosarcoma**
    - **Mieloma Multiplo**
- **Atropatie Articolari:**
  - **Artriti:**
    - **Reumatoide**
    - **Osteoartrosi**
    - **Altre**
- **Denti e Mascelle:**
  - **Carie**
  - **Parodontite**
  - **Ascesso**
  - **Ipoplasia**
  - **Cisti**
  - **Odontomi**
- **Deformazioni:**
  - **Poliomelite**
  - **Displasia Congenita dell’Anca**

Malattie “Ossee”

- **Disfunzioni Endocrine:**
  - **<u>Iperpituitarismo:</u>**
    - **Gigantismo**
    - **Acromegalia**
  - **<u>Ipopituitarismo:</u>**
    - **Nanismo (Armonico)**
- **Effetti della Dieta:**
  - **Rachitismo**
  - **Osteomalacia**
  - **Altre**
- **Affezioni di Origine Incerta:**
  - **Malattia di Paget**
  - **Osteoporosi**
- **Disordini Ematici**
- **Difetti Congeniti :**
  - **Acondroplasia**
  - **Idrocefalia**
  - **Acrocefalia**
  - **Microcefalia**
  - **Altre**
- **Sinostosi di Origine Incerta:**
  - **Scafocefalia**
  - **Altre**

Infiammazioni: Osteomielite

Infiammazione del tessuto osseo spugnoso

Infiammazioni: Periostite

Infiammazione del tessuto osseo compatto e della membrana che lo circonda (Periostio)



B *The left and right fibulae of a medieval skeleton from Scarborough. The right shaft displays extra bone formation resulting from periostitis.*

Infiammazioni: Tubercolosi

Infezione batterica, attacca polmoni, sistema linfatico ed ossa

Plate 6.3 Vertebral destruction and deformity in a pre-Columbian Indian, probably caused by tuberculosis. (By courtesy of Dr W. A. Ritchie.)

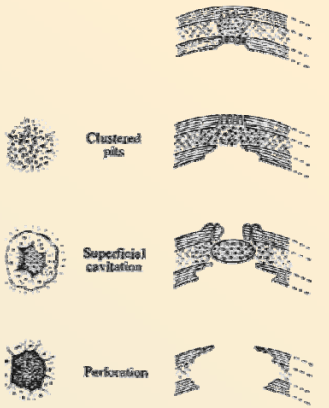

Figure 6.2 Tuberculosis sequence in skull bones. (Redrawn from Hackett.)

Infiammazioni: Frambesia



Plate 6.1
A. Swollen ulna right and worsted happened, as a female Veddah from Ceylon. It is very probable that the individual suffered from yaws.

Infezione batterica, distrugge ossa, sistema linfatico ed epidermide

Plate 6.4 A, Palatal region of a female Veddah with considerable palatal destruction caused by yaws. B, Prehistoric skull from the Western Pacific showing a crater-like lesion possibly due to yaws. (By courtesy of Dr T. D. Stewart and Dr A. Spoehr.) C, Frontal region of an Australian aboriginal showing similar lesions. (By courtesy of Dr T. D. Stewart and Dr A. Spoehr.) D, An Australian aboriginal skull with extensive infection and destruction of the vault and palatal regions, probably through yaws. E, Skull of a Gaboon Negro with considerable palatal destruction. Diagnosis in this case is difficult to establish.

Infiammazioni: Sifilide

Infezione batterica, distrugge ossa, sistema linfatico ed epidermide, oltre che mucose di organi interni





Figure 6.4 Syphilis sequence in long bones.
(Redrawn from Hackett.)

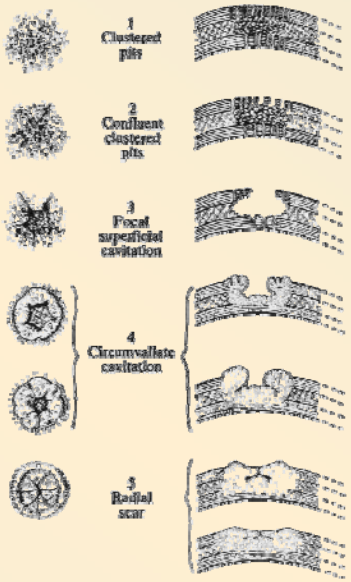

Figure 6.1 Syphilis sequence in skull bones.
(Redrawn from Hackett.)

Infiammazioni: Lebbra

Pericolosa infezione, distrugge tutti gli organi interni ed ogni tipo di tessuto. Forme più o meno gravi

Plate 6.5 Bone changes in leprosy. The skull and feet from a Danish medieval skeleton (Case I from Naestved). (By courtesy of Dr V. Møller-Christensen.)

Tumori Benigni: Osteoma

Formazione di escrescenze e tuberosità ossee soprattutto sul cranio

Tumori Maligni: Osteosarcoma

Aggressione e divoramento del tessuto osseo e del sistema linfatico circostante, grande facilità nel dare metastasi

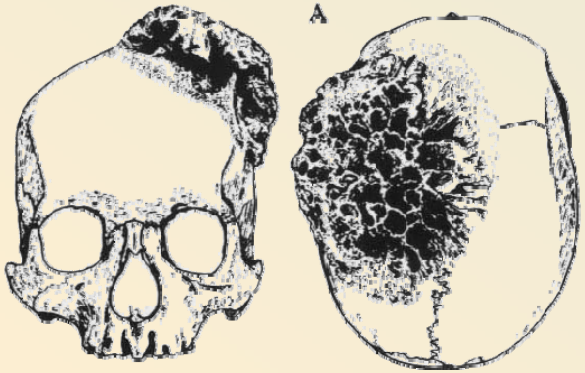

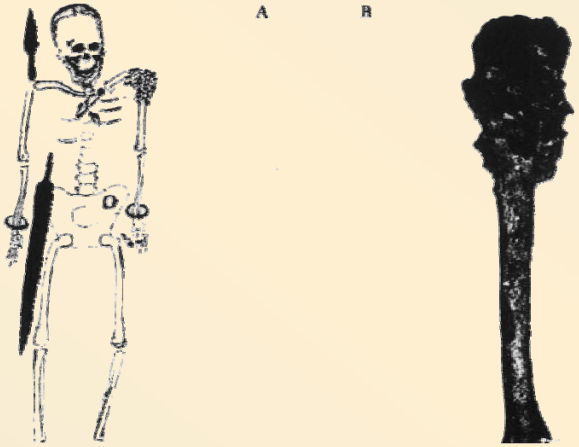

Tumori Maligni: Mieloma

Perforazioni delle ossa in più punti con rischi di infezioni e necrosi

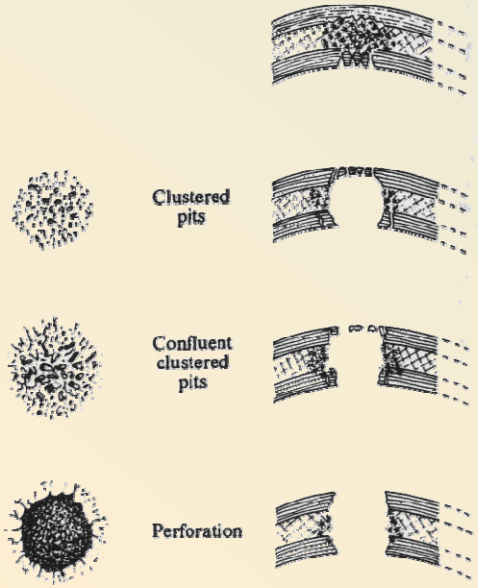

Figure 6.3 Metastatic neoplasm sequence for comparison with treponemal changes of the skull (Redrawn from Hackett.)



C

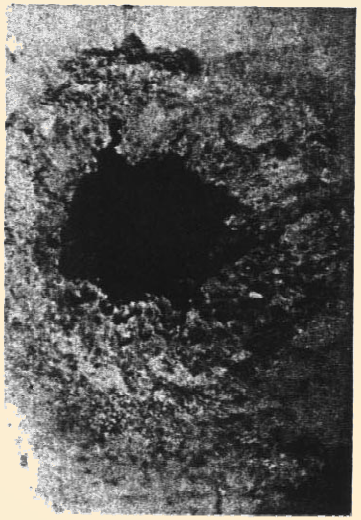

D

Artropatie Articolari: Artriti

Deposito a seguito di infiammazione di cristalli di Calcio sulle ossa delle articolazioni, rendendole inservibili (mani, piedi)

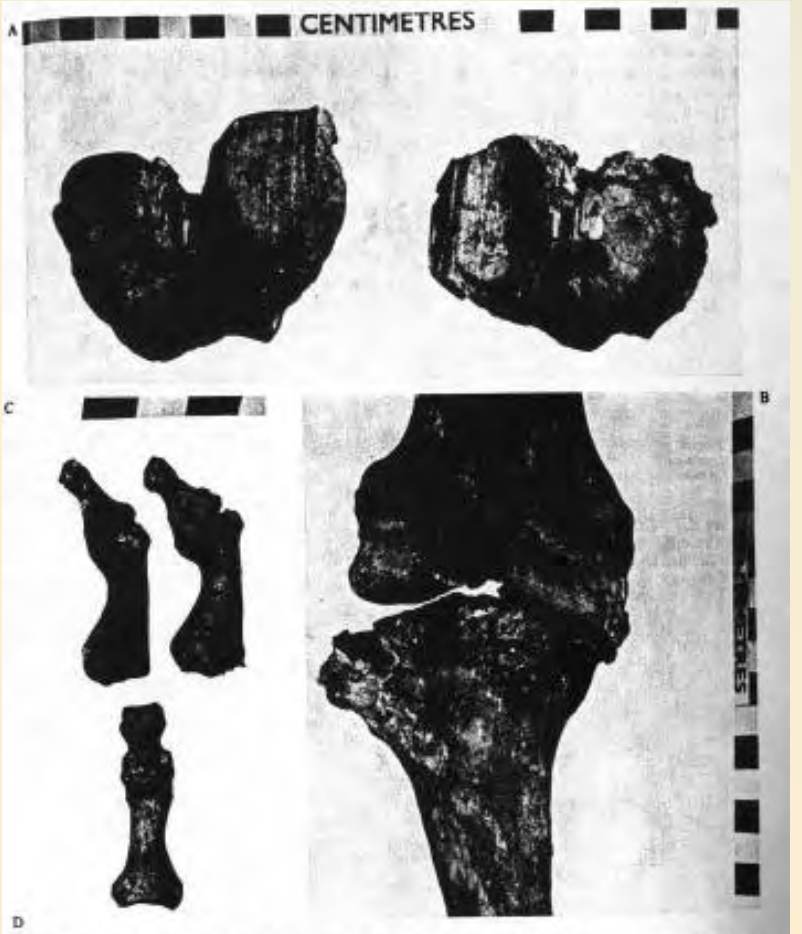

Plate 6.8 Rheumatic changes in bones. A–B, Severe osteoarthritis in a medieval male from Scarborough. A, Articular surfaces of the femur and tibia (at the knee) showing osteoarthritic lipping and considerable eburnation (through the movement of bone on bone). B, Posterior aspect of the knee showing 'lipped' margins of the condyles. C–D, Fused phalanges resulting from arthritis.

Artropatie Articolari: Osteoartrosi

- **Deposito a seguito di infiammazione di cristalli di Calcio sulle ossa delle articolazioni, rendendole inservibili (colonna vert.), dovuto a stress meccanico, troppo o errato uso**

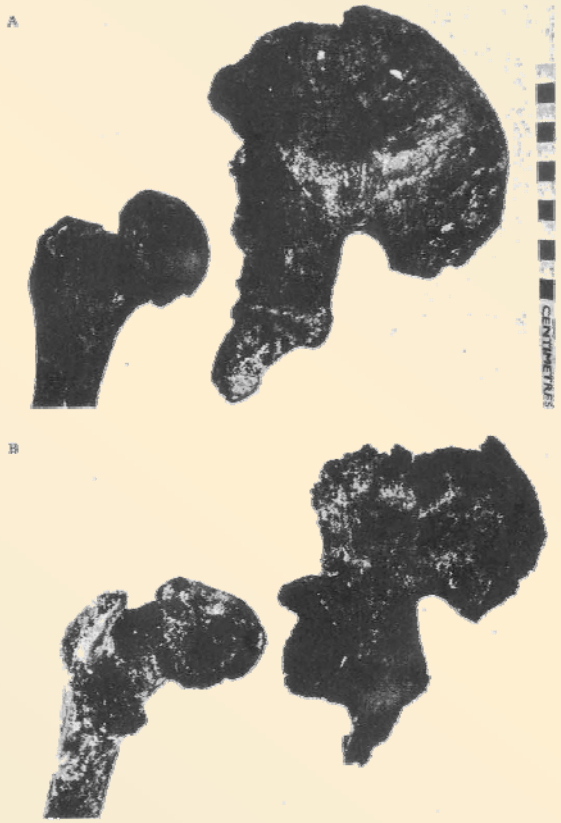

Plate 6.10 Abnormalities of the hip. A, Abnormally shallow acetabulum and deformed femoral head, possibly indicative of a partial dislocation. Anglo-Saxon. Guildown. B, Severe osteoarthritis of the hip in a Romano-Britain. Note the very "lipped" acetabulum and deformed femur head.

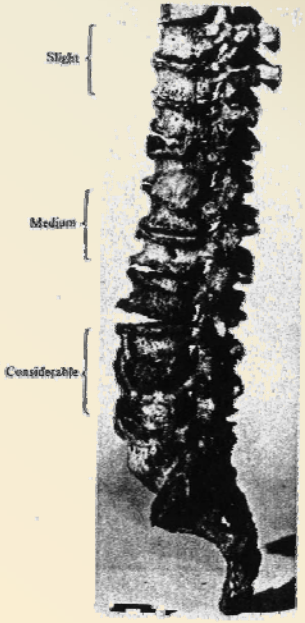

Plate 6.9 The vertebral column of a pre-medieval skeleton from Cambridge, showing various degrees of osteoarthritic 'lipping'.

Artropatie Articolari: Osteocondrite Dessicante

Frammentazione ossea con necrosi tissutale della componente organica dell'osso



Plate 6.11 Pitting of the articular surface characteristic of osteochondritis desiccans in phalange bones from Tean, Dark Age skeleton.

Denti e Mascelle: Carie

Aggressione batterica dello smalto fino a giungere alle radici, dovuta a cattiva pulizia e a dieta non corretta

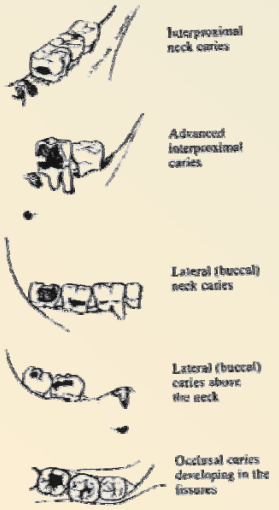

Figure 6.12 Sites of caries development in teeth.

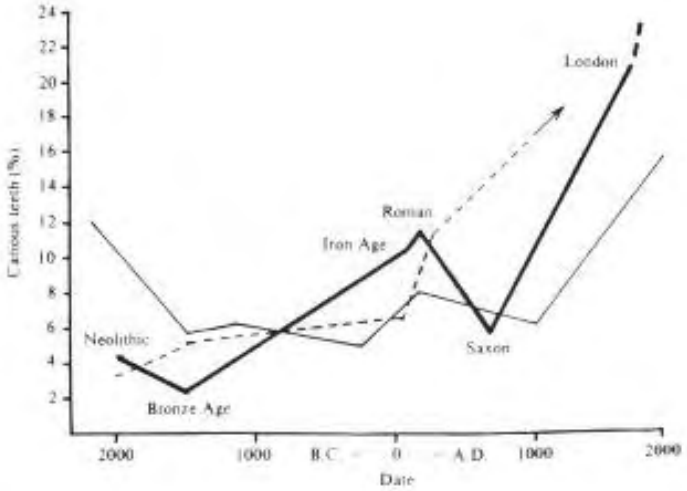

Figure 6.10 Caries frequencies through time in three areas. Mainly of young adults of both sexes. Britain: ▬; Greece: —; France: - - -.

Denti e Mascelle: Parodontite

Infezione dell'alveolo e dei tessuti molli della bocca: porta le radici dei denti in evidenza

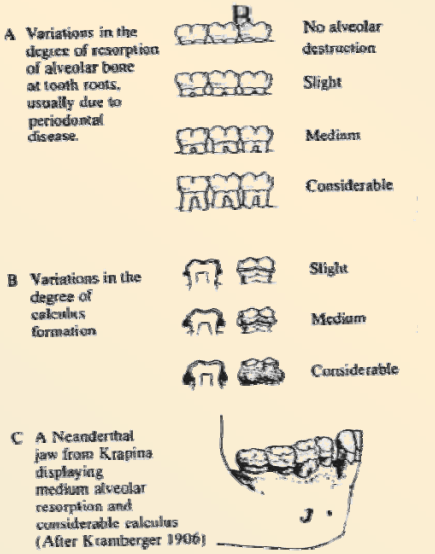

Figure 6.14 Stages of A, alvelor resorption and B, calculus formation. C, mandible from Krapina showing alveloar resorption and calculus formation.

Denti e Mascelle: Ascessi

Risultato di un’infezione che ha generato pus, con corrosione del tessuto osseo

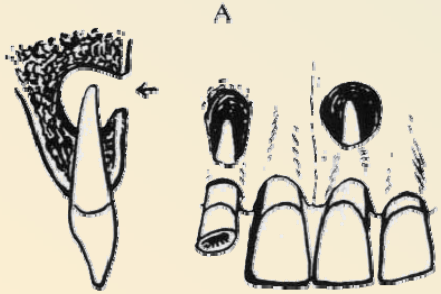

Denti e Mascelle: Odontoma

Tumore tipico degli alveoli, divora il tessuto osseo circostante

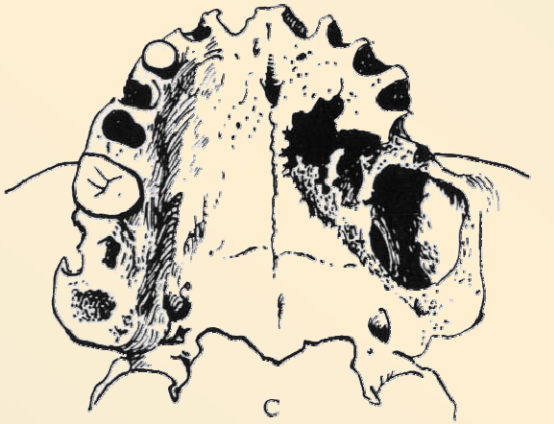

Malformazioni (coste, sterno)

Errato sviluppo durante la vita intrauterina (primi 3 mesi, embrione)

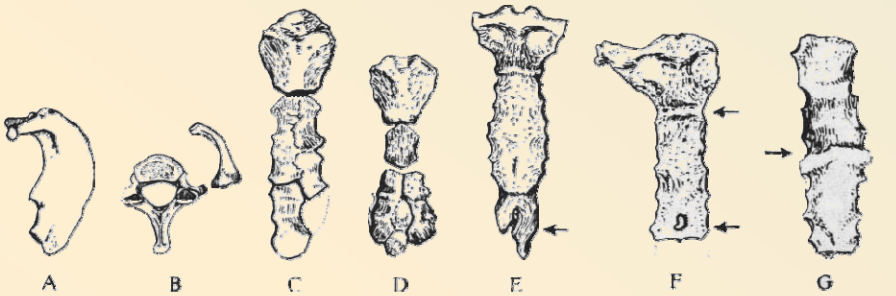

Figure 6.20 A, anomalous ribs (fused except in the articular region) from an Australian aboriginal. B, seventh cervical vertebra and its cervical rib from a Romano Briton. C, D, anomalous sterna from early Nubian skeletons. In each case, the sternal body is composed of a number of segments (after G. Elliot Smith & F. Wood Jones). E, ossified xiphosternum. Fairly common. F, sternum of an Anglo-Saxon, showing a perforation of the sternal body, and a fused manubrium. G, sternal body of an early Nubian, showing an old healed fracture (after G. Elliot Smith & F. Wood Jones).

Malformazioni (colonna vert.)

- **Errato sviluppo durante la vita intrauterina (primi 3 mesi, embrione)**

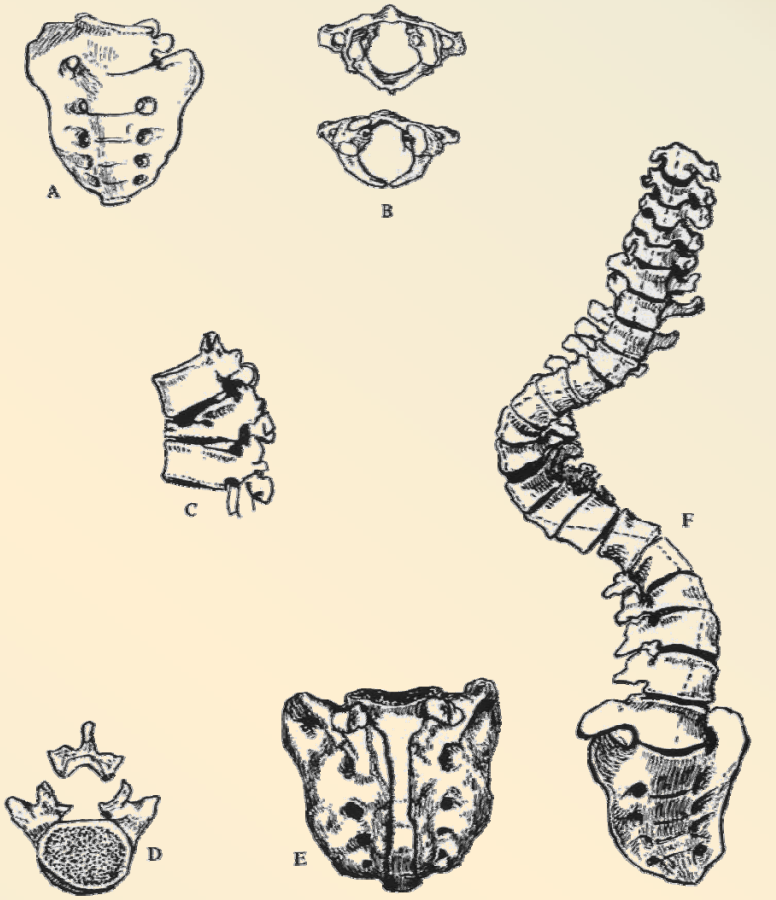

Figure 4.18 Anomalies of the vertebral column. A, partly sacralized lumbar vertebra. B, normal and anomalous atlas vertebrae from Lapps. C, collapsed vertebra of an Eskimo (after T. D. Stewart). D, separate neural arch in a lumbar vertebra of a Lapp. E, congenital exposure of the sacral canal in an Anglo-Saxon. F, well-marked vertebral scoliosis (after J. P. Weinmann & H. Sicker).

Malformazioni: Palatoschisi

- **Errato sviluppo durante la vita intrauterina (primi 3 mesi, embrione)**

B

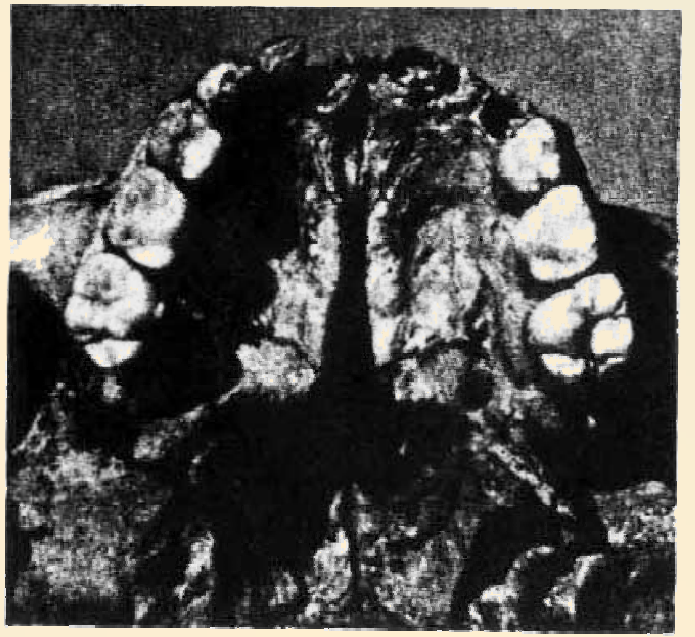

Deformazioni: Fratture

Rotture di ossa con saldature evidenti a carico del tessuto, talvolta limitanti nei movimenti e nell’uso della parte colpita (in genere arti)

Sist. End.: Acromegalia

Ripresa crescita in età adulta causa spesso tumore all'Ipofisi. Sproporzione testa - mani – piedi rispetto al resto del corpo

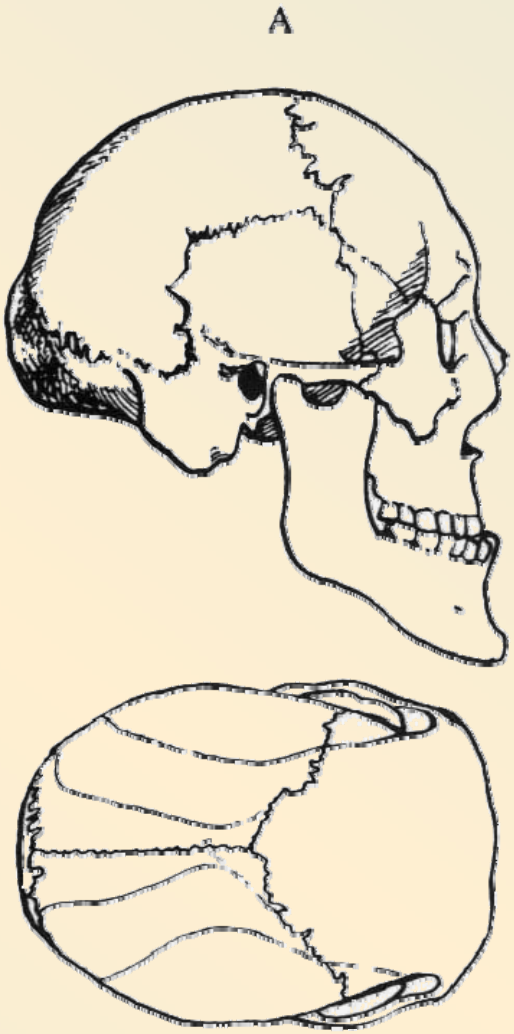

Sist. End.: Nanismo (armonico)

Mancato funzionamento dell’ipofisi, con limitata o assente secrezione di ormone della crescita

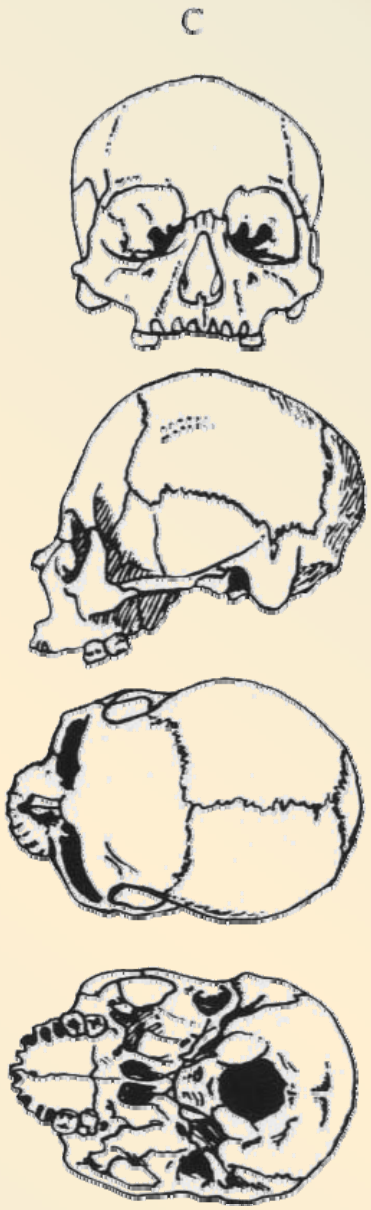

Dieta: Rachitismo

Mancato apporto di calcio e vitamina D durante la crescita con difetti di saldatura delle ossa e sproporzione di parti del corpo, soprattutto testa

Dieta: Difetti di Accrescimento

- Evidenza di linee di fermato accrescimento per problemi di salute o malnutrizione presso epifisi ossa lunghe, varie cause

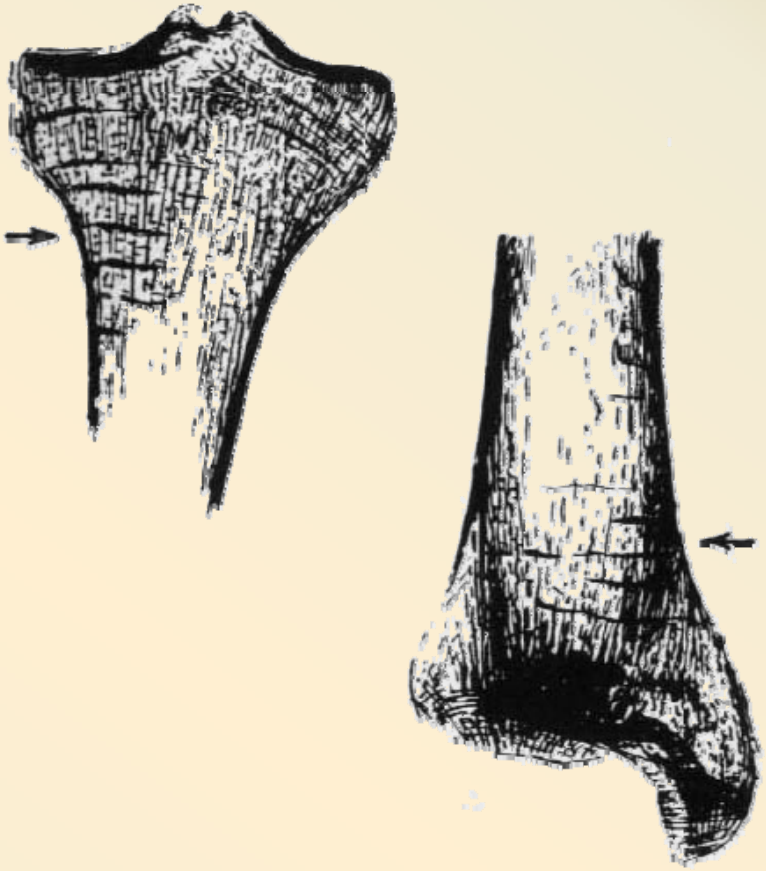

Figure 3.6 Radiographs of the proximal (above) and distal (below) ends of a pre-Roman tibia, showing well marked lines of arrested growth (arrowed).

Aff. Inc.: Malattia di Paget

Anomala sostituzione durante la crescita del tessuto osseo compatto con quello spugnoso: ossa fragilissime

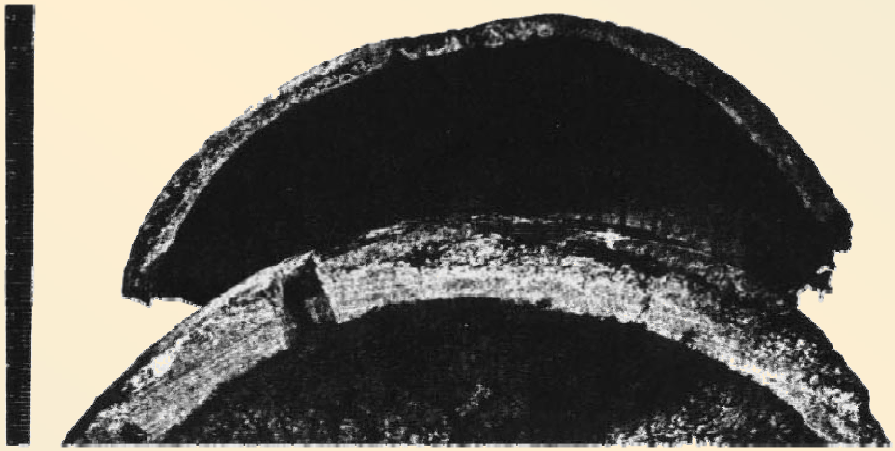

Aff. Inc.:Osteoporosi

Aumento numero e grandezza pori ossei, mancanza di calcio e vit. D, dieta errata



Disordini Ematici

Talassemia e Anemia Falciforme danno problemi di sviluppo durante la crescita con perforazione e fragilità ossea

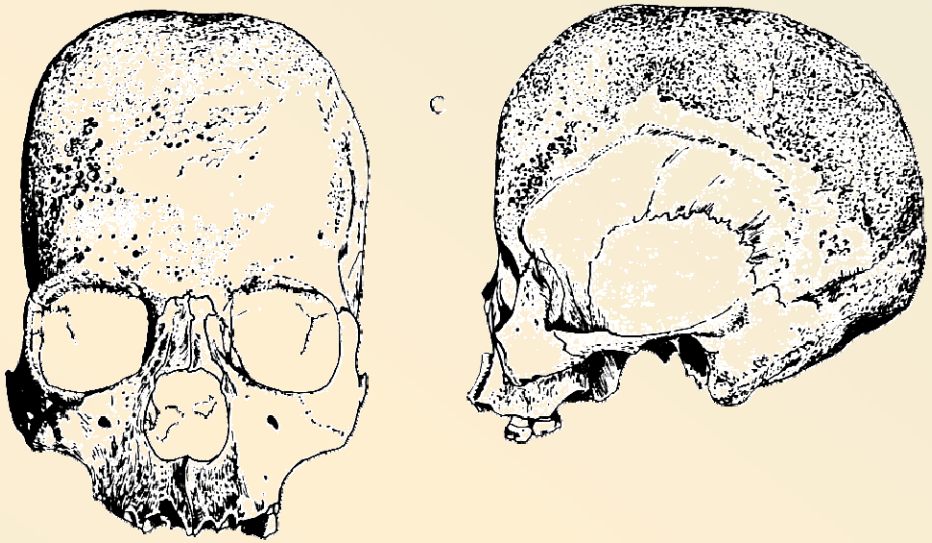

Dif. Cong.: Acondroplasia

Mancato sviluppo delle cartilagini ossee, con precoce ossificazione. Sproporzioni vistose, ossa robuste

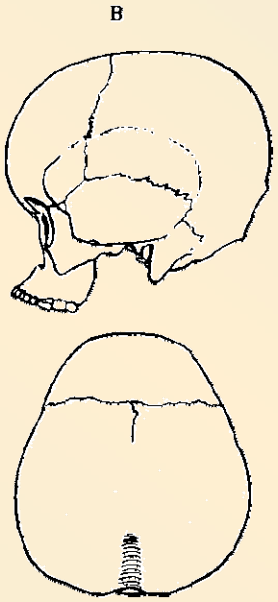

Dif. Cong.: Idrocefalia

Liquor nei ventricoli non drenato: aumento capacità scatola cranica con compressione centri nervosi e ritardo mentale più o meno accentuato

Dif. Cong.: Acrocefalia

Crescita anomala lungo sutura coronale con fusione anticipata delle ossa del cranio

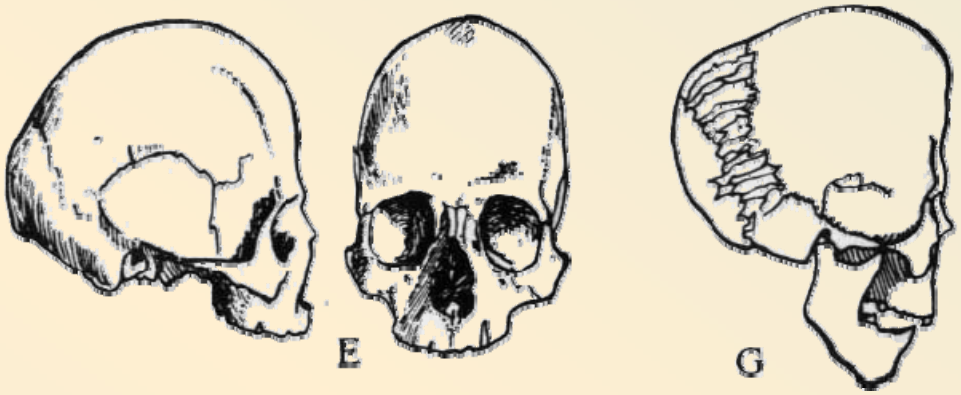

Dif. Cong.: Microcefalia

Dovuta a precoce chiusura delle suture craniche, con mancata crescita e possibili ritardi mentali

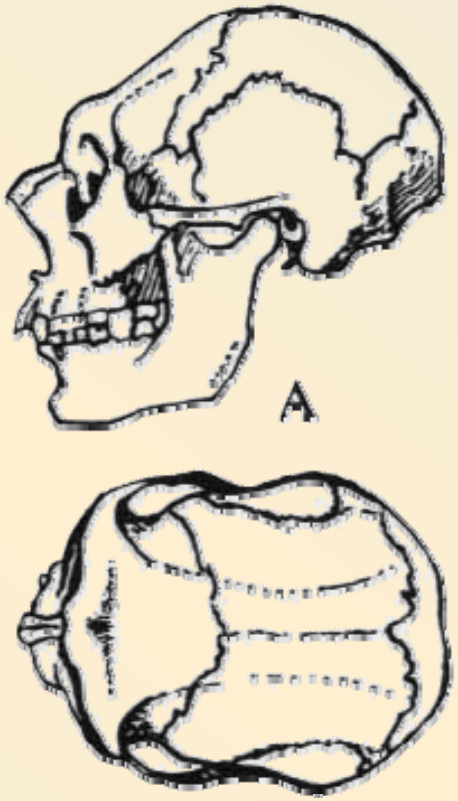

Dif. Cong: Agenesia Otica

Mancanza apertura meato acustico esterno. Può o meno essere sviluppato l’apparato uditivo interno

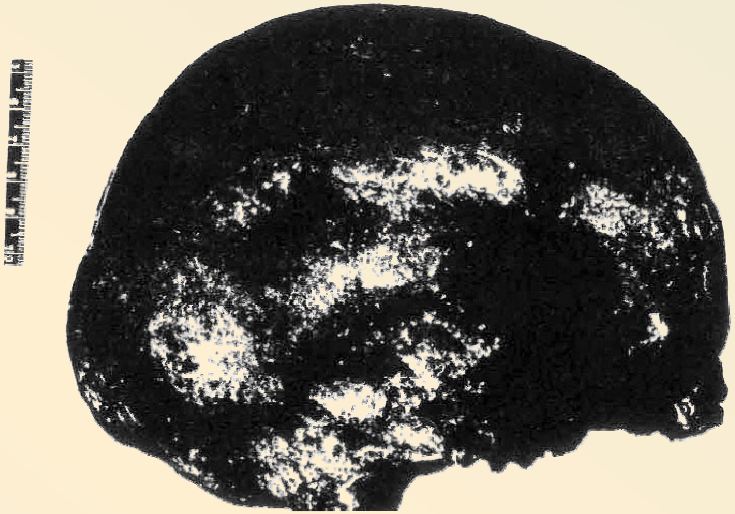

…ed anche questa è finita...

(... sperando di non aver fatto rimpiangere a nessuno la tv!!!)